



Genotype Distribution of Human Papillomavirus in Warts

Fauzia Perveen^{1*}, Saeda Baig¹ and Mohiuddin Alamgir²

¹Department of Biochemistry, Ziauddin Medical College, Ziauddin University, 4/B, Shakra-e-Ghalib, Block 6 Clifton, Karachi, 75600, Pakistan.

²Department of Pathology, Bahria University Medical and Dental College, Karachi, Pakistan.

Authors' contributions

This review is the result of collaborative work of all authors. Authors FP and SB conceived the idea. Author FP did the literature searches and wrote the first draft. Authors SB and MA edited and finalized the manuscript. All authors read and approved the final manuscript.

Article Information

DOI: 10.9734/BJMMR/2016/25384

Editor(s):

(1) Mohammed Rachidi, Molecular Genetics of Human Diseases, French Polynesia, University Paris 7 Denis Diderot, Paris, France.

(2) Sinan INCE, Department of Pharmacology and Toxicology, University of Afyon Kocatepe, Turkey.

Reviewers:

(1) Anonymous, McGill University, Canada.

(2) Maria Cristina de Melo Pessanha Carvalho, University Federal do Rio de Janeiro, Brazil.

(3) Jonatas Rafael de Oliveira, Sao Paulo State University, Brazil.

(4) Virginia Sánchez Monroy, Universidad del Ejército y Fuerza Aérea, Mexico.

(5) Luigi Tagliaferro, Laboratory "Dr. P. Pignatelli", Italy.

Complete Peer review History: <http://sciencedomain.org/review-history/14663>

Review Article

Received 29th February 2016

Accepted 9th May 2016

Published 17th May 2016

ABSTRACT

HPV warts, non-cancerous, epidermal growths, are caused by the virus by generally entering the skin through areas where the skin is broken, fragile or extremely moist making the top layer of skin to grow rapidly, forming a wart. There are more than 200 genotypes of HPV and about 100 genotypes have been identified in different types of warts. Generally, HPV infection, in most people resolves itself within two years without causing any serious health issue but when HPV becomes active it may invade mucous membrane leading to warts or other serious consequences. Since prevalence of HPV varies significantly and exact genotype distribution of HPV in different warts is still not clearly defined, this review aims to assess the distribution of HPV genotypes in different warts, their clinical presentation, diagnosis and treatment.

*Corresponding author: E-mail: fauzrehmani@gmail.com;

Keywords: Butcher; cancer; condyloma; epithelial; facial; feet; hyperplasia; HPV; oral; papilloma; squamous-cell; warts.

Duration of publications used: 2000 to 2016.

Databases used: Google Scholar and Pubmed.

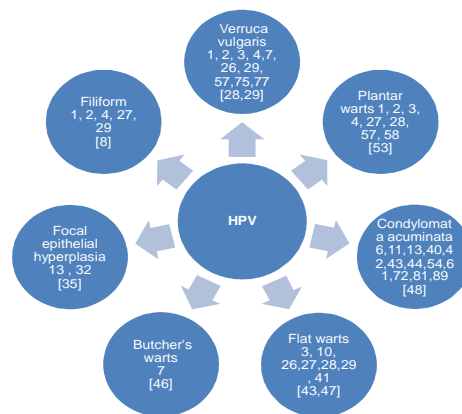
1. INTRODUCTION

HPV (Human Papilloma Virus); ‘papillomata’ may be sessile or pedunculated; generically, these will referred to by the common ubiquitous term ‘warts’. HPV warts, with their area specific distribution properties are found on different parts of body and are named according to their location and clinical appearance. Such as common warts which grow most frequently on the hands, periungual warts around nails and plantar warts grow on the soles of feet. HPV resides in the epithelium by entering the skin through areas where the skin is broken, fragile or extremely moist. HPV infects the squamous layer of epithelium, and causes the outer most layer of the skin to grow rapidly, forming a wart. Warts are flat and thin cells found on the skin surfaces and also on the surface of the vagina, anus, vulva, cervix, penis head, mouth, and throat. About 195 human papillomavirus genotypes have been sequenced and recognized [1]. About 60 genotypes can cause warts on the hands or feet. Remaining types of HPV transmitted sexually and are responsible for spreading this infection to the moist genital and anal areas [2].

HPV infection can be transmitted through sexual or asexual behaviour [3,4]. Smokers, tobacco chewers, male and people with weak immune system are at a greater risk of acquiring this infection [5]. Most commonly they occur in children, young adults and people with weak immune system such as HIV positive patients but they can occur at any age [6-8]. Since prevalence of HPV varies significantly and exact genotype distribution of HPV in different warts is still not clearly defined, this review aims to assess the distribution of HPV genotypes in different warts, their clinical presentation, diagnosis and treatment.

2. DISCUSSION

Human papillomavirus (HPV) is known etiologic agent for bringing about different warts shown in Fig. 1 [8,9,10,11,12,13-15,16]. Skin warts are most commonly caused by HPV 1, 2, 3, 4, 27 and 57. Verruca vulgaris are most prevalent (70%) in children, while plantar (myrmecias) and flat warts (verruca plana) are prevalent in older people [17].



HPV pathologies may manifest in any of the seven forms circled. The associated causal HPV numbered genotypes involved for each form are included in each circle. Some types occur in more than one form, for example, HPV 29 is found in flat warts, filiform warts, and in verruca vulgaris.

Fig. 1. HPV genotypes associated with warts

HPV is a non-enveloped, circular, double-stranded DNA virus. It is related to the papillomaviridae family. HPV genotypes are divided into five genera: Alphapapillomavirus, Betapapillomavirus, Gammapapillomavirus, Mupapillomavirus and Nupapillomavirus. About 200 additional viruses have also been identified that await sequencing and classification [18]. According to International Agency for Research on Cancer (IARC) HPV 1, 2, 3, 4, 6, 7, 10, 11, 13, 16, 18, 30, 31, 32, 33, 35, 45, 52, 55, 57, 59, 69, 72 and 73 are linked with warts and other benign and malignant lesions [19]. HPV 16 is an established cause of carcinomas of cervix, penis, vulva, vagina, anus and head and neck especially oropharyngeal carcinomas (OPC) [20,21]. The Population Attributable Fraction varies by geographic region, increasing to 6.9% in less developed areas of the world, 15.5% in India and 14.2% in sub-Saharan Africa compared with 2.1% in more developed areas, 1.2% in Australia/New Zealand and 1.6% in Northern America [21]. OPC commonly arise from base of the tongue and tonsils and increase incidence of OPC worldwide is due to increase in HPV [22]. HPV 16 is the most frequent genotype worldwide but distribution of different genotypes may differ according to geographic location [23]. According to a study in China, the most prevalent HPV genotypes in genital warts are HPV-6, HPV-11 and HPV-16 [24].

3. Oral Warts

Many HPV types have been repeatedly reported involved with warts, while HPV 1, 2, 63, 27 were usually reported on normal skin [25]. In HIV-positive patients oral warts are mostly associated with HPV infection. A study suggested that the low risk HPV6/11 types are more common than the high risk HPV16, 18, and 31 [26]. Another retrospective study reported that an increase in oral warts can be seen as a complication of highly active antiretroviral therapy in HIV-positive patients (HAART) [27]. A survey reported the prevalence of human papillomavirus (HPV)-types, derived from expectorates of an oral rinse in the U.S. adult population, at 7.3% [28]. Oral sex is a well known cause of its transmission to the oral cavity [28]. People who practice oro-genital sex have an increase chance of contracting a HPV oral infection [29]. Oral condyloma acuminatum, oral verruca vulgaris (common wart), oral focal epithelial hyperplasia (Archard and Heck Disease), and oral squamous cell papilloma are all recognized as oral warts and discussed below.

3.1 Oral Condyloma Acuminatum

The most frequently involved genotypes are 6 and 11 but other types may also be found [30]. Condyloma acuminatum, also called as venereal wart is an infectious, sexually transmitted disease which appears as multiple small, white or pink nodules, which proliferate and form cauliflower-like growth in wet areas of the body for example the gingiva, lips, tongue, soft palate, genitalia, and other places [31]. This infection is rarely found in the oral cavity but people who have anogenital warts may transmit this infection by self-inoculation or through sexual contact. Fetomaternal transmission is also possible. Cigarette smoking or betel quid chewing are other predisposing risk factors to HPV infection [32]. They are more common in people who are in their second decade of life, but if present in children it may indicate sexual abuse [17,33]. They may cause oropharyngeal, anogenital, or cervical cancer [34]. Treatment includes surgical excision, cryosurgery, electrocautery, and laser excision [35].

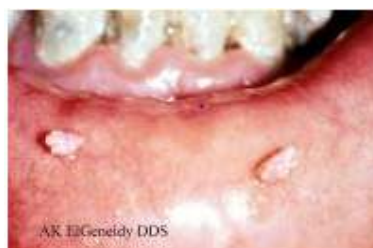

Fig. 2. Oral condyloma acuminatum

Two localized sessile papillomata on the alveolar mucosa of the lower lip. These are soft and may occur elsewhere in the oral cavity [<http://oralmaxillo-facialsurgery.blogspot.com/2010/05/viral-infections-of-mouth-cont-2.html>] (Accessed 7 April 2016)].

3.2 Oral Verruca Vulgaris

HPV types 1, 2, 4, 6, 7, 11 and 16 have been reported with verruca vulgaris [9,10]. Verruca vulgaris rarely occurs on the tongue [36], but if transmitted to the oral cavity, may appear as whitish sessile, circumscribed, exophytic papillomatous, hyperkeratotic lesions on the vermilion border of the lips, and/or on the labial mucosa of the lower lips or anterior part of the tongue [37]. Histologically, common warts exhibit hyperkeratosis, parakeratosis, papillomatosis and acanthosis. Treatment includes cryoablation,

chemical ablation, laser treatment but surgical excision is effective for verruca vulgaris [35,38].

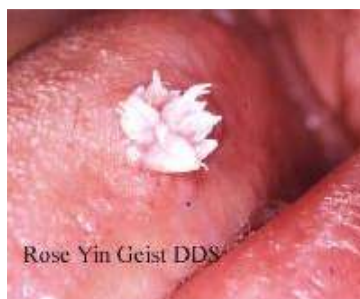

Fig. 3. Oral verruca vulgaris

This sessile, localized papilloma on the tongue shows multiple sharp projecting fronds; it is firm to touch, light pink to white in color and may vary in size. [<http://oralmaxillo-facialsurgery.blogspot.com/2010/05/viral-infections-of-mouth-cont-2.html>] (Accessed 7 April 2016)].

3.3 Oral Focal Epithelial Hyperplasia

Association of Focal epithelial hyperplasia (Archard and Heck disease) is found associated with HPV genotypes 13 and 32 [39]. HPV 13 has been found involved in all age groups, however, HPV-32 has been noted in elder patients as well [40]. Focal epithelial hyperplasia is also known as the Archard and Heck disease, These are characterized by multiple small sized, soft, white or pink, slightly elevated papules which are generally found on lower lip, oral mucosa, tongue, and hardly ever on the palate [11]. Patients may develop this infection at any age, but the most frequently affected age group is between 30 to 40 years of age [41]. Due to developing immunity, papillomata may degenerate in 1.5 years without any treatment; the few options for successful treatment include surgical removal, cryosurgery, laser surgery, topical podophyllum resin, and intra-lesional interferon [42].

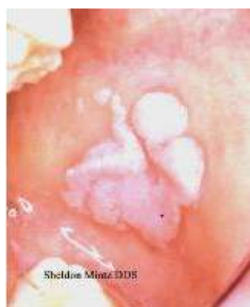

Fig. 4. Archard and heck disease

Multiple small, soft and slightly elevated pink papules are seen in the buccal mucosa of a 7-year-old boy. [<http://oralmaxillo-facialsurgery.blogspot.com/2010/05/viral-infections-of-mouth-cont-2.html>] (Accessed 7 April 2016)].

3.4 Oral Squamous Papilloma

Its association has been found with HPV genotypes 6 and 11 but the involvement HPV 58 has also been reported [43]. Oral squamous papilloma is a benign painless lesion of the oral cavity usually seen on the vermilion portion of the lips, soft palate, hard palate, lingual, frenulum, lower lip and uvula. They are single and less than 1cm in size papillary like projections which may show keratinization. Surgical removal is the treatment of choice. Topical use of imiquimod is another non-invasive treatment of multiple persistent oral squamous cell papillomas in HIV-patients [44].

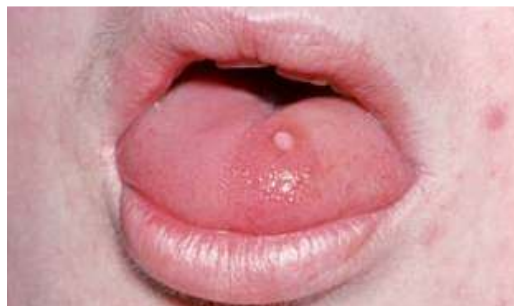

Fig. 5. Oral squamous papilloma

A single less than 1 cm in size papillary projection is seen on the dorsum of the tongue. [<http://www.clinicaladvisor.com/cmece-features/oral-lesions-caused-by-human-papillomavirus/article/193918/>] (Accessed 15 April 2016)].

4. FACIAL WARTS

4.1 Filiform Warts

Their association has been noted with HPV 2 [8]. They are flesh colored, rough or uneven, above the level of skin, and might be painful if pressed. The most frequent sites involved on face are around the eyelids and lips but may appear on neck as well this is the reason why they are considered very serious cosmetic defects. The most common symptoms are bleeding or itching. Facial warts can be treated with topical salicylic acid, trichloroacetic acid, and 5-fluorouracil, either alone or used in conjunction with

cryotherapy, surgical excision, or laser light. Treatment with oral Zinc Sulphate could be effective [45].

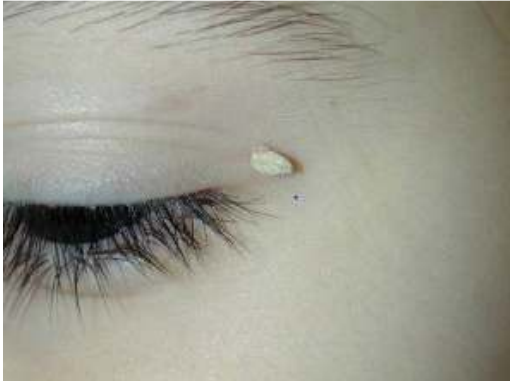

Fig. 6. Filiform warts

A rough or uneven projection is seen around the eyelids of a child. [<http://lagunaskincenter.Com/articles/warts/> (Accessed 15 April 2016)].

4.2 Flat Warts/Verruca Plana

Flat warts are associated with HPV 3, 10, 27, 28, 41 and 49 [46,47] and are also known as juvenile warts because they are not found in people above 40 years of age. These are smooth, flat and smaller in size as compare to other types and occur only in children and adolescents. On examination they look like flat growth similar to a mole. Patients may present with the complaint of itching. Step-up therapy of 5-aminolevulinic acid photodynamic can play a role with fewer side effects [12]. Removal of the upper parts of the hyperkeratotic wart lesions by CO₂ laser initially could enhance the absorption of the photosensitizer in this treatment [48].

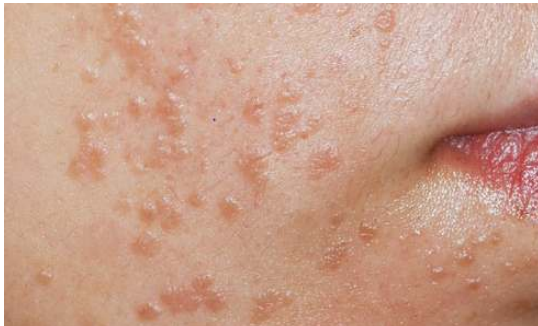

Fig. 7. Flat warts

Flat round or oval elevations of 1-2 mm above the skin and of 1 to 3 mm in diameter, color of

the growths is from skin color to pinkish brown. [<http://noskinproblems.com/flat-warts/> (Accessed 15 April 2016)].

5. HANDS/FINGER WARTS

5.1 Common Warts/Verruca Vulgaris

This type is associated with HPV 7 [49]. Common warts are the most frequently occurring warts on the hands but they might also appear anywhere on the body. The preference for the hands partially reflects the high likelihood that hands will contact a contaminated environmental surface during play or work. It is also caused by the natural tendency for young children to pick or scratch at existing warts, spreading them to unaffected skin, a process known as autoinoculation. Common warts occurring beneath the fingernails are called subungual warts, whereas around the fingernails are called periungual warts. These are also found on the hands of people who frequently handle raw meat hence named as Butcher's wart.

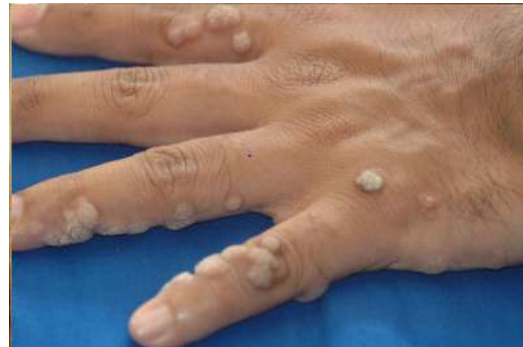

Fig. 8. Butcher's wart

These cauliflower shaped clusters on the hand and fingers are commonly seen in people who frequently handle meat. [[Http://trypophilia.tumblr.Com/post/99766668420/butchers-warts-those-who-frequently-handle-and#](http://trypophilia.tumblr.Com/post/99766668420/butchers-warts-those-who-frequently-handle-and#) (Accessed 15 April 2016)].

5.2 Flat Warts

Flat warts on the hands are induced by the human papillomavirus genotypes 3, 10, 28 and 49 [13]. These types of warts are usually seen more frequently in children and teens compared to adults. The warts are smooth, flat and small in size, round or oval but size vary from 2 to 5 mm in diameter. The color of flat warts could be pinkish, brown or yellowish pink. Most often these warts are seen in groups on the skin.

6. GENITAL/CONDYLOMA ACUMINATA

Genital warts are a sexually transmitted infection associated with human papillomavirus 6, 11, 13, 40, 42, 43, 44, 54, 61, 72, 81 and 89, but most frequently reported are 6 and 11 [14,15]. These are soft growths that occur on the genitals. The most frequently involved areas in males are penis, scrotum, groin, thighs, inside or around the anus and in females vagina, anus and cervix. Patient may suffer from discomfort, itching and pain. These are diagnosed by Pap smear. Genital warts may go away with time but few available options include some topical treatments such as imiquimod [50], podophyllin [51] and podofilox, and trichloroacetic acid [52] and if persist they may require surgical removal by burning, freezing, or laser. Any vaccine that contains HPV 6 & 11 genotypes can be used for prevention [50].

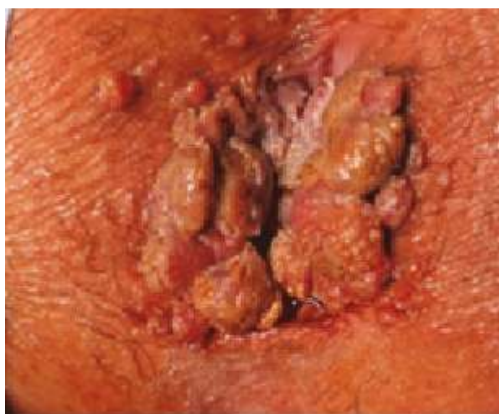

Fig. 9. Genital/condyloma acuminata

Genital warts found as flesh-colored bumps usually measure 1 millimeter to 2 millimeters in diameter on moist surfaces, especially at the entrance of the vagina and rectum in women but it can involve any anal or genital area in men and women. [<http://www.womenshealthmag.com/health/genital-warts-facts> (Accessed 7 April 2016)].

7. Foot Warts

Association of deep plantar warts/myrmecia has been reported most frequently with HPV 1 and 4 however HPV 57, 60, 63, 65, and 66 can also cause this infection [53]. Warts which are present on feet are called plantar or myrmecia. They are very painful and tender. Usually found on weight bearing areas especially on the sole of the feet. Plantar warts occur after the age of 5 years.

People may contract this infection through barefoot activities. Clinically they may present with a rim of keratin surrounding a softer keratotic plug, with scattered capillary points. Histologically, a disorganised granular layer, with koilocytic cells and parakeratotic cells with nuclear inclusions in the upper layers seen. It may bleed due to presence of these capillaries [16]. This can be treated by destructive methods, caustic acid, chemotherapeutic agents, hypersensitivity agents and miscellaneous agents such as salicylic acid preparations. A study reported that citric and nitric acids are beneficial against common warts [54].

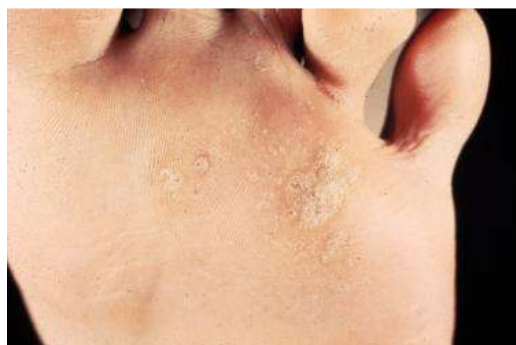

Fig. 10. Foot warts

Small shiny papules sharply defined, round with a rough keratotic surface are found on weight-bearing areas on the plantar surface. [<http://emedicine.medscape.com/article/1133317-clinical#b4> (Accessed 7 April 2016)].

8. DIAGNOSIS

The diagnosis of the warts can be made on clinical examination or with application of acetic acid and biopsy. Identification of human papillomavirus (HPV) DNA is presently affirmed by the US Food and Drug Administration (FDA) and is important as a screening device in females more seasoned than 30 years. Identification of genotypes with Polymerase chain reaction, Southern blot, Dot blot, and In situ hybridization can be made but is usually reserved for research purposes. Patients with condylomata acuminata don't require these lab techniques [8].

9. TREATMENT

There is no absolute cure for HPV virus infection, but like most other viral infections, prophylaxis through vaccines shows great promise to ensure

effective immune moderation. Two Vaccines [Gardasil (Merck Pharmaceuticals) and Cervarix (GlaxoSmithKline)] are available but these vaccines can only prevent future infection for few restricted strains. In 2014, the FDA approved Gardasil 9, which protects against nine HPV types including 6, 11, 16, 18, 31, 33, 45, 52, and 58. It is estimated that Gardasil 9 could prevent diseases associated with the vaccine HPV types [55]. No single treatment has been turned out to be successful. Oral isotretinoin might be viewed as a noninvasive option type of treatment for small condylomata acuminata [56]. MMR vaccine can be considered as a safe, effective, inexpensive intralesional immunotherapeutic modality in the treatment of wart [57]. Surgical removal of these warts by Loop Electrosurgical Excision Procedure (LEEP), conization or cryotherapy can be helpful. These procedures only remove the evident symptoms of the HPV infection by treating them with liquid nitrogen, removal by a CO2 laser or a surgical scalpel, or electrical current to treat the infected cells [12]. Planter warts can be removed surgically or treated with mono-, di- or tri-chloroacetic acid, podophyllotoxin, bleomycin, dinitrochlorobenzene /DNCEB, diphenylcyprone, immune response modifiers, imiquimod cream salicylic acid, tretinoin or cimetidine [54].

10. CONCLUDING REMARKS

It is noteworthy that same HPV genotypes can cause different types of warts in different body parts or locations. Such as type 1, 2 and 4 are causing common, plantar and facial warts. Hence if vaccines of these three genotypes be developed they can take care of all these wart types.

CONSENT

It is not applicable.

ETHICAL APPROVAL

It is not applicable.

COMPETING INTERESTS

Authors have declared that no competing interests exist.

REFERENCES

1. Hošnjak L, Kocjan BJ, Pirš B, Seme K, Poljak M. Characterization of two novel

- Gammapapillomaviruses, HPV179 and HPV184, isolated from common warts of a renal-transplant recipient. *PloS one*. 2015;10(3):e0119154.
2. Arroyo LS, Basaras M, Arrese E, Hernández S, Esteban V, Cisterna R. Distribution of genital human papillomavirus genotypes in benign clinical manifestations among men from Northern Spain. *BMC Public Health*. 2016;27;16(1):1.
 3. Irshad F, Syed S, Baig S. Perception of HPV in children. *Pak J Med Dent*. 2014; 3(1):48-52.
 4. Feller L, Khammissa RA, Wood NH, Lemmer J. Epithelial maturation and molecular biology of oral HPV. *Infectious Agents and Cancer*. 2009;4:16. Epub 2009/11/26.
 5. Mazumder TH, Nath S, Nath N, Kumar M. Head and neck squamous cell carcinoma: Prognosis using molecular approach. *Central European Journal of Biology*. 2014;9(6):593-613.
 6. Neme S, Wahome E, Mwashigadi G, Thiong'o AN, Stekler JD, Wald A, Sanders EJ, Graham SM. Prevalence, incidence, and clearance of anogenital warts in Kenyan men reporting high-risk sexual behavior, including men who have sex with men. In *Open Forum Infectious Diseases*. 2015;2(2):ofv070. Oxford University Press.
 7. Mulhall BP, Wright ST, De La, Mata N, Allen D, Brown K, Dickson B, Grotowski M, Jackson E, Petoumenos K, Foster R, Read T. Risk factors associated with incident sexually transmitted infections in HIV-positive patients in the Australian HIV observational database: A prospective cohort study. *HIV Medicine*; 2016.
 8. Mittal A, Mehta S. Human papillomavirus and hepatitis A, B, and C infections. *Comprehensive Approach to Infections in Dermatology*. 2016;12:239.
 9. Terai M, et al. Oral wart associated with human papilloma virus type 2. *Journal of Oral Pathology and Medicine*. 2007;28(3): 137-140.
 10. Kumaraswamy KL, Vidhya M. Human papilloma virus and oral infections: An update. *Journal of Cancer Research and Therapeutics*. 2011;7(2):120.
 11. Nelson BL, Schafer DR, Bosy TZ. The typing of the human papillomavirus within an older patient population. Abstract 0897. Presented at the IADR/AADR/CADR 80th General Session. San Diego, CA; 2002.

12. Qian G, Wang S, Deng D, Yang G. Is the step-up therapy of topical 5-aminolevulinic acid photodynamic therapy effective and safe for the patients with recalcitrant facial flat wart? *Dermatologic Therapy*. 2014; 27(2):83-8.
13. Olsen JS. Inventor; v-biotek holding APS, assignee. Extract of *trigonella foenum-graecum*. United States Patent US 20,160,000,845; 2016.
14. Wiley DJ, Douglas J, Beutner K, Cox T, Fife K, Moscicki AB, Fukumoto L. External genital warts: Diagnosis, treatment and prevention. *Clinical Infectious Diseases*. 2002;35(Supplement 2):S210-24.
15. Garland SM, Steben M, Sings HL, James M, Lu S, Raiikar R, Barr E, Haupt RM, Joura EA. Natural history of genital warts: Analysis of the placebo arm of 2 randomized phase III trials of a quadrivalent human papillomavirus (types 6, 11, 16, and 18) vaccine. *Journal of Infectious Diseases*. 2009;199(6):805-14.
16. Heather A. Cubic Diseases Associated with Human Papillomavirus Infection. DOI: 10.1016/J.VIROL.2013.06.007
17. Touyz LZG. Human Papilloma Virus (HPV)-A biological and clinical appraisal. *Science Postprint Japan*. 2013;1(1): e00001. DOI: 10.14340/spp.2013.10R0002
18. Chouhy D, Bolatti EM, Pérez GR, Giri AA. Analysis of the genetic diversity and phylogenetic relationships of putative human papillomavirus types. *Journal of General Virology*. 2013;94(Pt 11):2480-8.
19. International Agency for Research on Cancer (IARC). *Monographs on the Evaluation of Carcinogenic Risks to Humans*. Lyon, France. 2011;100.
20. Rollison DE, Gillison ML. The alpha, beta, gamma of oral human papillomavirus infection and head and neck cancer risk. *JAMA Oncology*; 2016.
21. Pringle GA. The role of human papillomavirus in oral disease. *Dental clinics of North America*. 2014;30; 58(2):385-99.
22. Dahlstrom KR, Sturgis EM. Epidemiology of oral HPV infection and HPV-associated head and neck cancer. In *HPV and Head and Neck Cancers*. 2015;13-39. Springer India.
23. Salehi-Vaziri M, Sadeghi F, Hashemi FS, Haeri H, Bokharaei-Salim F, Monavari SH, Keyvani H. Distribution of human papillomavirus genotypes in Iranian women according to the severity of the cervical lesion. *Iranian Red Crescent Medical Journal*; 2016. (In press).
24. Chang L, Ci P, Shi J, Zhai K, Feng X, Colombara D, Wang W, Qiao Y, Chen W, Wu Y. Distribution of genital wart human papillomavirus genotypes in China: A multi-center study. *Journal of Medical Virology*. 2013;85(10):1765-74.
25. Koning MN, Quint KD, Bruggink SC, Gussekloo J, Bouwes Bavinck JN, Feltkamp MC, Quint WG, Eekhof JA. High prevalence of cutaneous warts in elementary school children and the ubiquitous presence of wart-associated human papillomavirus on clinically normal skin. *British Journal of Dermatology*. 2015;172(1):196-201.
26. Hua Xi, Kou Qiang, Yi Xue, Za Zhi, Ma SC, Hu J, Zhao J, Speight P: Typing human papilloma virus (HPV) infection in the warts of oral mucosa from HIV-positive patients. 2004;22(5):423-5.
27. Greenspan D, Canchola AJ, MacPhail LA, Cheikh B, Greenspan JS. Effect of highly active antiretroviral therapy on frequency of oral warts. *Lancet*. 2001;357(9266): 1411-2.
28. Sanders A, Slade G, Patton L. National prevalence of oral HPV infection and related risk factors in the US adult population. *Oral Diseases*. 2012; 18(5):430-41.
29. Bharti AH, Chotaliya K, Marfatia YS. An update on oral human papillomavirus infection. *Indian Journal of Sexually Transmitted Diseases and AIDS*. 2013;34(2):77.
30. Kennedy RA. HPV for the oral surgeon. *Oral Surgery*; 2015.
31. Henn IW, Galina F, Chaiben CL, Kula J, dos Santos JN, de Lima AA. Multiple oral condyloma acuminatum in a patient with HIV/AIDS—A case report. *Polski Przegląd Otorinolaryngologiczny*. 2014;3(3):160-4.
32. Jaiswal R, Pandey M, Shukla M, Kumar M: Condyloma acuminatum of the buccal mucosa. *Ear, Nose, & Throat Journal*. 2014;93(6):219-223. Ana Clélia Cãnovas Percinoto, Marcelle Danelon, Marcelo Macedo Crivelini, Robson Frederico Cunha, Célio Percinoto: Condyloma acuminata in the tongue and palate of a sexually abused child: A case report. *BMC Res Notes*. 2014;7:467. Published online 2014 July 23.

34. Bechtel MA, Trout W. Sexually transmitted diseases. (Clin Obstet Gynecol). 2015; 58(1):172-84.
DOI: 10.1097/GRF.0000000000000078
35. Prabhu SR, Wilson DF. Human papillomavirus and oral disease—emerging evidence: A review. Australian Dental Journal. 2013;58(1):2-10.
36. Ural A, Arslan S, Ersoz Ş, Değer B. Verruca vulgaris of the tongue: A case report with a literature review. Bosn J Basic Med Sci. 2014;14(3):136-8.
DOI: 10.17305/bjbm.2014.3.29
37. Forman D, de Martel C, Lacey CJ, Soerjomataram I, Lortet-Tieulent J, Bruni L, et al. Global burden of human papillomavirus and related diseases. Vaccine. 2012;30(Suppl 5):F12–23. [PubMed].
38. Gleason AG, Ponce DM, Gasparil DV. Diagnosis and treatment of solitary tongue papilloma. Case report and literature review. Revista Odontológica Mexicana. 2016;20(1):39-43.
39. Khot KP, Deshmane S, Choudhari S. Human papilloma virus in oral squamous cell carcinoma—the enigma unravelled. Chin J Dent Res. 2016;19(1):17-23.
40. Gnepp DR. Diagnostic surgical pathology of the head and neck, 2nd edition. Philadelphia: Saunders elsevier. 2009;252-257.
41. Barikbin B, Tehraninia Z, Mozafari N. Treatment of multifocal epithelial hyperplasia with imiquimod. Indian Journal of Dermatology, Venereology, and Leprology. 2014;80(2):175.
42. Sabeena S, Pallade SR, Kamath N, Mathew M, Arunkumar G. Papilloma of lip associated with human papilloma viruses-32 infection in a child. Indian J Med Microbiol. 2016;34:97-9.
43. Wheat CM, Bickley RJ, Cohen BA. Pediatric dermatology photoquiz: Multiple papules on the mucosal surfaces of a 17-year-old boy. Pediatric Dermatology. 2016;33(1):91-2.
44. Esquivel-Pedraza L, Fernández-Cuevas L, Saeb-Lima M, Guerrero-Ramos BA, Hernández-Salazar A, Méndez-Flores S. Recalcitrant oral squamous cell papilloma lesions in two HIV-infected patients successfully treated with topical imiquimod. Journal of Dermatological Case Reports. 2015;9(1):19.
45. Ali AM. Assessment of the effect of oral zinc sulfate treatment for viral warts on serum level of TNF alpha.
46. Kim BR, Woo SM, Yoon HS, Cho SY, Park HS. Development of facial flat warts at a completely healed site of trauma: Wolf's isotopic response-like phenomenon. International Journal of Dermatology. 2015;54(1):e43-4.
47. Cubie HA. Diseases associated with human papillomavirus infection. Virology. 2013;445(1):21-34.
48. Yoo KH, Kim BJ, Kim MN. Enhanced efficacy of photodynamic therapy with methyl 5-aminolevulinic acid in recalcitrant periungual warts after ablative carbon dioxide fractional laser: A pilot study. Dermatol Surg. 2009;35:1927-1932.
49. Bonifazi E. Differential diagnosis in pediatric dermatology. Springer Science & Business Media; 2013.
50. Park IU, Introcaso C, Dunne EF. Human papillomavirus and genital warts: A review of the evidence for the 2015 centers for disease control and prevention sexually transmitted diseases treatment guidelines. Clinical Infectious Diseases. 2015;15; 61(suppl 8):S849-55.
51. Chhachhi H, Gupta AK, Singh SK, Patel RK, Patel PK, Kumar R, Kumar A. The sociodemographic characteristics, clinical profile and treatment records of anogenital warts in eastern uttar pradesh—a retrospective evaluation from treatment records at a tertiary centre.
52. Clarke L, Nandwani R. P183 Trichloroacetic acid (TCA)—a forgotten treatment for genital warts? Sexually Transmitted Infections. 2015;91(Suppl 1):A76.
53. Doorbar J, Egawa N, Griffin H, Kranjec C, Murakami I. Human papillomavirus molecular biology and disease association. Reviews in Medical Virology. 2015; 25(S1):2-3.
54. Parasuraman S. Effect of nitric acid on cutaneous and plantar warts—a case report. Journal of Young Pharmacists. 2016;8(2):159.
55. Joura EA, Giuliano AR, Iversen OE, Bouchard C, Mao C, Mehlsen J, Moreira Jr ED, Ngan Y, Petersen LK, Lazcano-Ponce E, Pitisuttithum P. A 9-valent HPV vaccine against infection and intraepithelial

- neoplasia in women. New England Journal of Medicine. 2015;372(8):711-23.
56. Tsambaos D, Georgiou S, Monastirli A, Sakkis TH, Sagriotis A, Goerz G. Treatment of condylomata acuminata with oral isotretinoin. The Journal of Urology. 1997;158(5):1810-2.
57. Raju J, Swamy AV, Swamy BN, Raghavendra KR. Keywords: immunotherapy, mmr vaccine, wart. Intralesional measles, mumps and rubella (Mmr) vaccine-an effective therapeutic tool in the treatment of wart. 2015;23(93707).

© 2016 Perveen et al.; This is an Open Access article distributed under the terms of the Creative Commons Attribution License (<http://creativecommons.org/licenses/by/4.0>), which permits unrestricted use, distribution, and reproduction in any medium, provided the original work is properly cited.

Peer-review history:

The peer review history for this paper can be accessed here:
<http://sciencedomain.org/review-history/14663>