



Distal Humeral Shear Fracture - A Modified Technique for Exposure

**A. Raviraj¹, Vidyasagar Mallepati¹, K. Abhishek Sugumar¹,
Vivek Kumar N. Savsani¹, Ajith N. Prabhu¹ and Ashish Anand^{2,3,4*}**

¹Apollo Hospitals, Bannerghata Road, Bangalore-560076, India.

²VA Medical Center, Jackson, USA.

³University of Mississippi Medical Center, Jackson, MS, USA.

⁴William Carey School of Osteopathic Medicine, Hattiesburg, MS, USA.

Authors' contributions

This work was carried out in collaboration among all authors. Authors AR, VM and AA designed the study, performed the statistical analysis, wrote the protocol and wrote the first draft of the manuscript. Authors KAS, VKNS, ANP and VM managed the analyses of the study. Authors AR and AA managed the literature searches. All authors read and approved the final manuscript.

Article Information

DOI: 10.9734/JAMMR/2019/v30i1130249

Editor(s):

(1) Dr. Ravi Kumar Chittoria, Department of Plastic Surgery and Advanced, Centre For Microvascular, Maxillofacial & Craniofacial, Laser Surgery, Jawaharlal Institute of Postgraduate Medical Education and Research, Pondicherry, India.

Reviewers:

(1) Mahrukh Kamran, Dow University of Health Sciences, Pakistan.

(2) Francesco Manfreda, Università degli Studi di Perugia, Italy.

Complete Peer review History: <http://www.sdiarticle4.com/review-history/52479>

Case Report

Received 01 September 2019

Accepted 03 November 2019

Published 05 November 2019

ABSTRACT

Coronal shear fractures of the distal humerus are rare, complex fractures that can be technically challenging even in the best of hands. Their peak incidence is seen in elderly females and is usually the result of low energy fall. The injury is usually part of complex elbow injury and in rare instances can be isolated entity. Complex injury pattern is characterized by shear fracture combined with fracture of radial head and collateral ligament injury. The preferred treatment for this complex fracture is Open reduction and internal fixation. The usual recommendation is a two-incision approach.

We report a rare case in which fracture could not be classified using the traditional classification systems and in which entire fracture was managed via a single approach.

Keywords: Coronal; shear; fractures; distal; humerus; management; approach; two-incision.

1. INTRODUCTION

Distal humerus fractures are commonly seen in young adults and elderly population. The mechanism of injury is high energy trauma in young adults [1] and low energy fall in elderly [1-2]. With increase in baby boomers population number of elderly people with this fracture has increased. The preferred treatment in a young adult is Open reduction and internal fixation (ORIF) utilizing the standard principles. The guiding principle is Rigid fixation and early mobilization and minimal surgical trauma while exposing the fracture fragments [3-5]. The rationale behind early mobilization is to prevent worsening of Post traumatic osteoarthritis [5]. The trauma surgeon has numerous options as regards kind of implant fixation, however the implant usage is dictated by fracture anatomy and comminution. Current standard of care in young adults is use of pre contoured anatomical locking plates which can either be applied in 90-90 configuration or parallel configuration [6-9]. Having Rigid fixation at time of surgery doesn't equate with a good outcome and complications rates in young adults can be as high as 35 Percent [6-9].

Fractures in elderly population and usually females is characterized by extensive comminution, osteopenia and soft tissue damage and hence even use of standard implants which suffice for young population might fail in this population [3]. Complication rates in this subset of population can be higher than young adults [10]. Low demand elderly population with osteopenia and extensive comminution are best managed by Total Elbow arthroplasty (TEA) [11,12]. TEA is recommended as locking plates can fail in these patients and at their age one is better off by doing a single surgery in low demand individuals [13-15].

This fracture pattern is usually classified using the Dubberly classification or Ring classification [16-21]. The preferred surgical approach is lateral [3] although a two- incision approach is also described [18]. We describe a rare case of a complex injury-distal humerus coronal shear fracture involving the capitellum and trochlea along with medial column injury. There was no posterior condylar communication or collateral ligament injury and this injury does not come under the commonly used Dubberly or Ring

classifications. We describe the surgical technique in such a complex injury.

2. CASE REPORT

A 30 years old gentle man presented to ER of our tertiary care hospital with a right elbow injury after a motor vehicle accident. Patient did not have any distal neurological or vascular deficits. It was a closed fracture. The radiographs and computer tomography (Figs. 1 and 2) revealed, complex shear fracture of the distal humerus with involvement of capitellum and trochlea and also the medial column. The patient did not have any head injury or any other fractures.

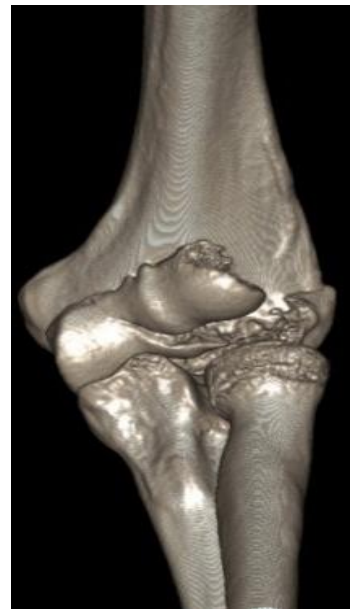

Fig. 1. Ct scan showing fracture configuration

Considering his age, he was offered Open reduction and internal fixation (ORIF) with use of locking plates. He underwent ORIF using olecranon osteotomy and under general anesthesia. As collateral ligaments were intact which made visualization of anterior capitellar fragment impossible. To avoid second incision we elevated the common extensor origin and Lateral collateral ligament thereby exposing the anterior shear component of capitellum. This gave a wide exposure of distal and antero-lateral exposure thereby allowing reduction of fragments in coronal plane. Preliminary reduction was confirmed under image intensifier and

provisionally fixed with k wires. The fracture fixation was performed from posterior to anterior using multiple headless Herbert screws (Synthes) and Bio k wire (Zimmer). Osteotomy was fixed with 6.5 cancellous screw and would be closed in layers (Fig. 3). Patient was placed in an above elbow splint for a weeks and then mobilization was started .He was followed periodically and x rays were done. Fracture and osteotomy were healed at around 10 weeks. At his last follow up at 1 year his range of motion was 5 to 120 degrees. He did not have any instability issues (Fig. 4).

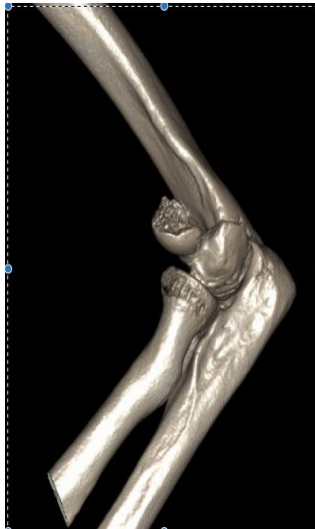


Fig. 2. Ct scan showing fracture

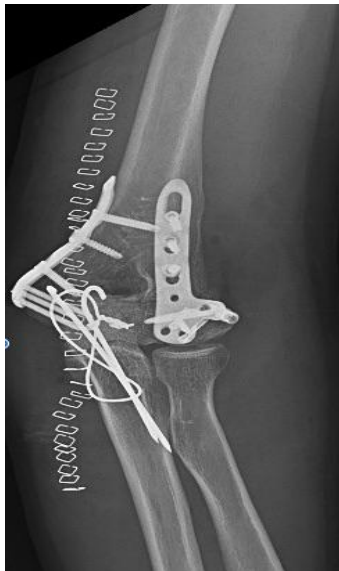

Fig. 3. Immediate postoperative fixation

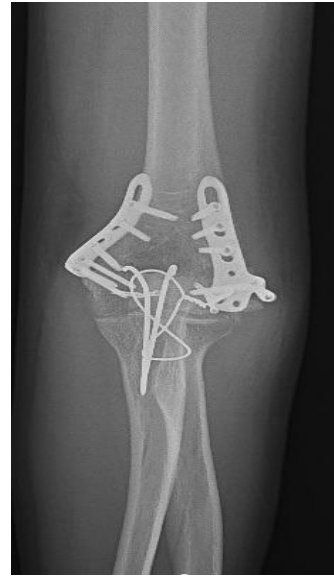

Fig. 4. X-ray at final follow up

3. DISCUSSION

Distal humerus fractures is a complex injury pattern and is usually caused by high energy injury in a young adult. They are classified using one of the three classification systems-Morrey [5], Dubberly [8] or Ring, et al. [9].

Morrey et al classified the injury into 4 grades-Gr1 is characterized by large piece of trabecular bone with attached capitellar cartilage. Grade 2 is characterized by small piece of cartilage and wafer of bone. Grade 3 is characterized by compression of capitellum and comminution. Grade 4 was a late addition to this classification and is characterized by a coronal shear fracture involving entire capitellum and portion of trochlea.

Dubberly classification entails Type 1 involving primarily the capitellum with or without lateral trochlear ridge involvement. Type 2 is a fracture of capitellum and trochlea in a single piece where the fracture extends in the coronal plane across the capitellum to include most of the lateral trochlear ridge and the lateral half of the trochlea-essentially [20]. Type 3 involves fractures of both the capitellum and the trochlea as separate fragments. The fractures are further subdivided into type (A) or (B) depending on absence or presence of posterior condylar comminution, respectively.

Ring Classification classifies the fracture into 5 grades-Grade 1a coronal shear fracture

comprised of single articular fragment that includes the capitellum and the lateral portion of the trochlea. Grade 2 includes an associated fracture of the lateral epicondyle. Grade 3 characterized by impaction of the metaphyseal bone behind the capitellum in the distal and posterior aspect of the lateral column. Grade 4 adds a fracture of the posterior aspect of the trochlea to the above. Type 5 includes a fracture of the medial epicondyle.

The varied treatment modalities range from non-operative which is usually done in elderly patients who are not surgical candidates [1-3]. The standard of care for these kinds of fractures involves ORIF. ORIF can be done via Kocher approach, usually indicated for fractures without significant posterior comminution or medial column damage [8,10-11].

The posterior approach with an olecranon osteotomy can be used when an articular fracture extends to the medial epicondyle combined with significant posterior comminution or medial column damage [8,10-11]. Sometimes a posterior approach without osteotomy is recommended if future procedures or arthroplasty is anticipated [10]. Good outcomes have been described for both approaches [3,10-15].

An anterolateral approach is also described as it avoids disruption of Lateral Ulnar Collateral ligament (LUCL) and olecranon osteotomy [14-16] and have reported good outcomes as well. There have been selected case reports suggesting use of arthroscopy for reduction and fixation and are recommended for Dubberly Grade 1 A and Dubberly Grade 3 A [16-19].

More recently a two incision technique has been proposed which uses the interval between Extensor digitorum and Extensor carpi radialis brevis. Subsequently capsule is incised anterior to LUCL and if tightness is observed then annular ligament is incised as well. For fixation of coronal component, a small limited anterior incision is made at elbow crease, subsequently plane between biceps and neurovascular bundle is identified, trochlea is palpated, and split made in brachialis over the trochlea. Subsequent capsulectomy is done to reduce and fix fragments.

Total Elbow arthroplasty is indicated in elderly patients with comminution and osteopenia [20-23] with good reported outcomes.

Excision as a treatment modality is indicated for small fragments which cannot be fixed [23] and is generally not preferred.

A critical review of the CT scan indicates that our patients fracture could not be slotted into one of the classification systems. To gain a wide exposure we initially did an olecranon osteotomy. Olecranon osteotomy did not reveal the anterior extent of capitellar fracture as collateral ligament was intact. To enhance visualization we did subperiosteal elevation of LUCL thereby allowing adequate exposure and allowing fixation of fragments. This way we were able to avoid second anterior incision.

4. CONCLUSION

The two standard approaches to gain access to Trochlea and capitellum involves either disruption of LUCL or olecranon osteotomy. However, if olecranon osteotomy has been attempted and visualization is poor than one needs to do a subperiosteal elevation of LUCL rather than splitting it to gain adequate exposure. This also avoids second anterior incision.

CONSENT

As per international standard, patient's written consent has been collected and preserved by the author(s).

ETHICAL APPROVAL

As per international standard, ethical approval has been collected and preserved by the author.

COMPETING INTERESTS

Authors have declared that no competing interests exist.

REFERENCES

1. Nauth A, McKee MD, Ristevski B, Hall J, Schemitsch EH. Distal humeral fractures in adults. *J Bone Joint Surg Am.* 2011; 93:686–700.
2. Lee JJ, Lawton JN. Coronal shear fractures of the distal humerus. *J Hand Surg Am.* 2012;37:2412–2417.
3. Ruchelsman DE, Tejwani NC, Kwon YW, Egol KA. Coronal plane partial articular fractures of the distal humerus: Current concepts in management. *J Am Acad Orthop Surg.* 2008;16:716–728.

4. Watts AC, Morris A, Robinson CM. Fractures of the distal humeral articular surface. *J Bone Joint Surg Br.* 2007; 89:510–515.
5. O'Driscoll SW, Morrey BF, Korinek S, An KN. Elbow subluxation and dislocation. A spectrum of instability. *Clin Orthop Relat Res.* 1992;(280):186–197.
6. Guitton TG, Doornberg JN, Raaymakers EL, Ring D, Kloen P. Fractures of the capitellum and trochlea. *J Bone Joint Surg Am.* 2009;91:390–397.
7. Ruchelsman DE, Tejwani NC, Kwon YW, Egol KA. Open reduction and internal fixation of capitellar fractures with headless screws. *Surgical technique. J Bone Joint Surg Am.* 2009;91(Suppl 2 Pt1):38–49.
8. Ring D, Jupiter JB, Gulotta L. Articular fractures of the distal part of the humerus. *J Bone Joint Surg Am.* 2003;85-A:232–238.
9. Dubberley JH, Faber KJ, Macdermid JC, Patterson SD, King GJ. Outcome after open reduction and internal fixation of capitellar and trochlear fractures. *J Bone Joint Surg Am.* 2006;88:46–54.
10. Goodman HJ, Choueka J. Complex coronal shear fractures of the distal humerus. *Bull Hosp Jt Dis.* 2005;62:85–89.
11. Bilsel K, Atalar AC, Erdil M, Elmadağ M, Sen C, Demirhan M. Coronal plane fractures of the distal humerus involving the capitellum and trochlea treated with open reduction internal fixation. *Arch Orthop Trauma Surg.* 2013;133:797–804
12. Sano S, Rokkaku T, Saito S, Tokunaga S, Abe Y, Moriya H. Herbert screw fixation of capitellar fractures. *J Shoulder Elbow Surg.* 2005;14:307–311
13. Mighell M, Virani NA, Shannon R, Echols EL, Badman BL, Keating CJ. Large coronal shear fractures of the capitellum and trochlea treated with headless compression screws. *J Shoulder Elbow Surg.* 2010;19:38–45.
14. McKee MD, Jupiter JB, Bamberger HB. Coronal shear fractures of the distal end of the humerus. *J Bone Joint Surg Am.* 1996; 78:49–54.
15. Imatani J, Morito Y, Hashizume H, Inoue H. Internal fixation for coronal shear fracture of the distal end of the humerus by the anterolateral approach. *J Shoulder Elbow Surg.* 2001;10:554–556.
16. Malki AA, Salloom FM, Wong-Chung J, Ekri AI. Cannulated screw fixation of fractured capitellum: Surgical technique through a limited approach. *Injury.* 2000; 31:204–206.
17. Hardy P, Menguy F, Guillot S. Arthroscopic treatment of capitellum fracture of the humerus. *Arthroscopy.* 2002;18:422–426.
18. Kuriyama K, Kawanishi Y, Yamamoto K. Arthroscopic-assisted reduction and percutaneous fixation for coronal shear fractures of the distal humerus: Report of two cases. *J Hand Surg Am.* 2010; 35:1506–1509.
19. Mitani M, Nabeshima Y, Ozaki A, Mori H, Issei N, Fujii H, Fujioka H, Doita M. Arthroscopic reduction and percutaneous cannulated screw fixation of a capitellar fracture of the humerus: A case report. *J Shoulder Elbow Surg.* 2009;18:e6–e9.
20. Shahram YS, Bowers NL, Craig M, Reichel LM. Management of distal humeral coronal shear fractures. *World J Clin Cases.* 2015;3(5):405–417
21. Kamineni S, Morrey BF. Distal humeral fractures treated with noncustom total elbow replacement. *Surgical technique. J Bone Joint Surg Am.* 2005;87(Suppl 1):41–50.
22. Reichel LM, Hillin CD, Reitman CA. Immediate Total Elbow Arthroplasty Following Olecranon Osteotomy: A case report. *Open J Orthop.* 2013;3:213–216.
23. Lee SK, Kim KJ, Park KH, Choy WS. A comparison between orthogonal and parallel plating methods for distal humerus fractures: a prospective randomized trial. *Eur J Orthop Surg Traumatol.* 2014; 24:1123–1131.

© 2019 Raviraj et al.; This is an Open Access article distributed under the terms of the Creative Commons Attribution License (<http://creativecommons.org/licenses/by/4.0>), which permits unrestricted use, distribution, and reproduction in any medium, provided the original work is properly cited.

Peer-review history:

The peer review history for this paper can be accessed here:
<http://www.sdiarticle4.com/review-history/52479>