



Thyroid Tuberculosis: A Unique Case Report

Ravi Talapa ^{a++*}, Nidhi Yadav ^{a++}, Siddhant Jain ^{a++},
Tanvi Sirohi ^{a#} and Shourya Yerramareddy ^{a++}

^a ABVIMS and Dr. RML Hospital, New Delhi, India.

Authors' contributions

This work was carried out in collaboration among all authors. All authors read and approved the final manuscript.

Article Information

DOI: <https://doi.org/10.9734/ajrid/2024/v15i6352>

Open Peer Review History:

This journal follows the Advanced Open Peer Review policy. Identity of the Reviewers, Editor(s) and additional Reviewers, peer review comments, different versions of the manuscript, comments of the editors, etc are available here: <https://www.sdiarticle5.com/review-history/117633>

Case Report

Received: 14/03/2024
Accepted: 17/05/2024
Published: 22/05/2024

ABSTRACT

Tuberculosis affecting the thyroid gland is a rare occurrence, even in the regions where tuberculosis is prevalent. This case report details the presentation of a 22-year-old male who initially presented with a life-threatening condition of cardiac tamponade, ultimately diagnosed as thyroid tuberculosis. The case underscores the critical role of fine needle aspiration cytology (FNAC) in accurately diagnosing such uncommon manifestations of tuberculosis. This case highlights the significance of FNAC in confirming tuberculosis as the underlying cause of thyroid involvement, facilitating timely and targeted therapeutic interventions for patients presenting with unusual clinical manifestations of tuberculosis.

Keywords: Fine needle aspiration cytology (FNAC); cardiac tamponade; lymphadenopathy; disseminated tuberculosis; tuberculosis.

⁺⁺ Post Graduate Student;

[#] Senior Resident;

^{*}Corresponding author: E-mail: rtblaze1998@gmail.com;

Cite as: Talapa, R., Yadav, N., Jain, S., Sirohi, T., & Yerramareddy, S. (2024). Thyroid Tuberculosis: A Unique Case Report. *Asian Journal of Research in Infectious Diseases*, 15(6), 20–25. <https://doi.org/10.9734/ajrid/2024/v15i6352>

1. INTRODUCTION

Thyroid tuberculosis, is a rare form of extrapulmonary tuberculosis. Thyroid tuberculosis typically develops due to the spread of tuberculosis from other organs or tissues in the body, often through the bloodstream or lymphatic system and mainly associated with cervical lymphadenopathy [1,2]. The infection may result in the formation of nodules or abscesses within the thyroid gland.

2. CASE REPORT

A 22-year-old male presented with complaints of shortness of breath for 1 week, which had an insidious onset and was gradually progressive, associated with orthopnea. He had a significant history of weight loss (12 kg in 6 months) and loss of appetite, with no history of fever, cough, chest pain, or palpitations. There was no history of congenital heart disease, decreased urine output, or lower limb swelling. The patient denied any use of recreational drugs and had no family history of cardiac disease. He had a history of abdominal tuberculosis in 2011 and completed the anti-tuberculosis treatment (ATT) course for 9 months.

On examination, the patient had a temperature of 98.2°F, pulse rate of 78/min, blood pressure of 90/60 mmHg, SPO2 of 97% on room air, and raised jugular venous pressure (JVP). The

patient had a thin build, with multiple palpable nodules in bilateral lobes of the thyroid gland along with multiple matted cervical lymph nodes. In systemic examination, the patient had muffled heart sounds with no murmur or pericardial rub; other systems were normal on examination. The ECG (Fig. 1) on admission showed low voltage complexes with electrical alternans. Chest X-ray (Fig. 2) showed an increased diameter of the cardiac impression (money bag appearance). 2D Echo confirmed our findings and suggested moderate pericardial effusion. A pericardial catheter was placed, and approximately 500 ml of light-yellow-colored fluid was drained. Cardiac troponin and CK-MB were negative. Other parameters on admission were: Hb - 12 g/dL, TLC - 7300/microliter, Platelets - 4.9 lakh/microliter, Urea - 16 mg/dL, Creatinine - 0.8 mg/dL, total bilirubin - 1 mg/dL, direct bilirubin - 0.3 mg/dL, total protein - 7.5 g/dL, albumin - 3.6 g/dL, Na - 137 mmol/L, K - 4.5 mmol/L, Ca - 8 mg/dL, PO4 - 3.6 mmol/dL, ESR - 21, total cholesterol - 70 mg/dL, HDL - 18 mg/dL, LDL - 39 mg/dL, triglyceride - 67 mg/dL, with normal iron profile and peripheral smear. Pericardial fluid study showed 200-250 cells, all lymphocytes, with a total protein of 5.7 g/dL, glucose - 109 mg/dL, albumin - 3 g/dL, LDH - 1023 U/L, ADA - 22.7. CBNAAT, gram stain, and culture were negative for tuberculosis. Malignant cytology of the fluid was also negative. The patient's autoimmune profile was negative, and retroviral test was non-reactive.

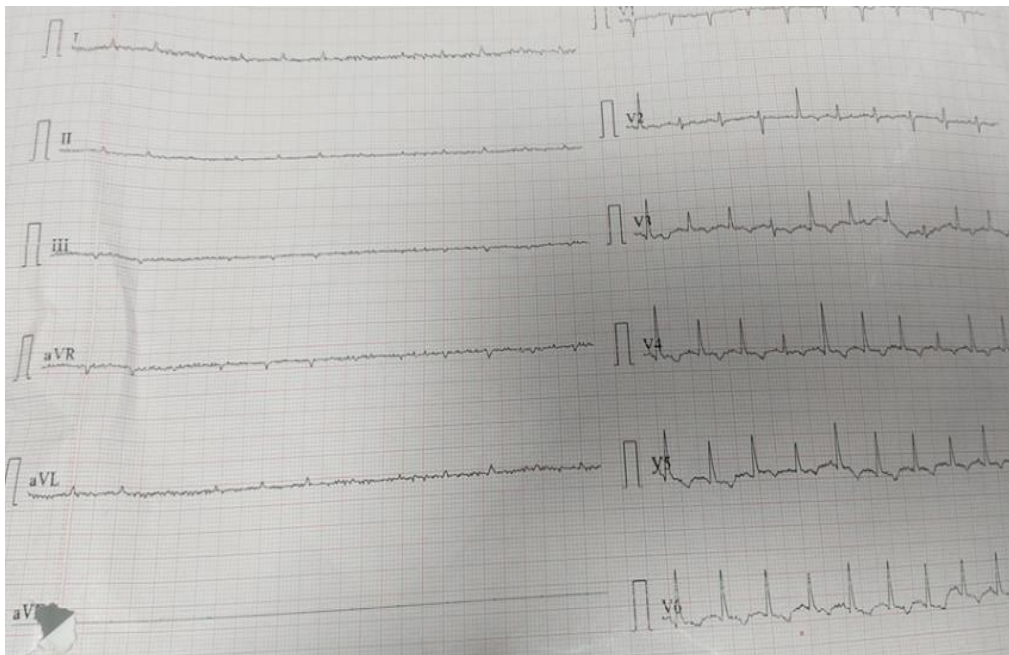


Fig. 1. ECG showing low voltage complexes with electrical alternance

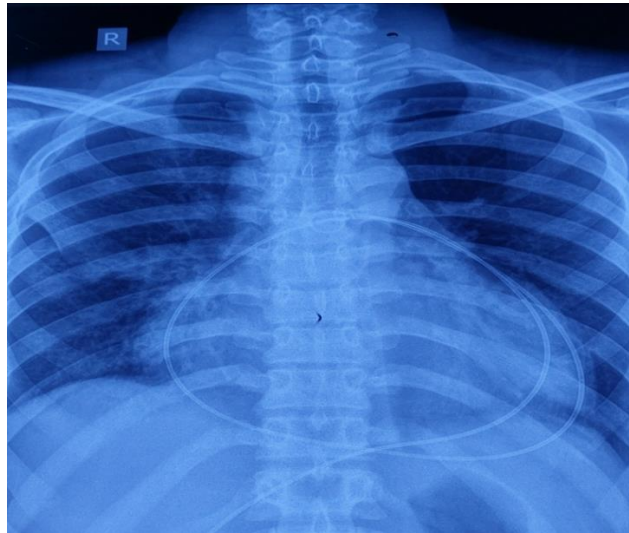


Fig. 2. Chest Xray PA view showing cardiomegaly with pericardial catheter in-situ

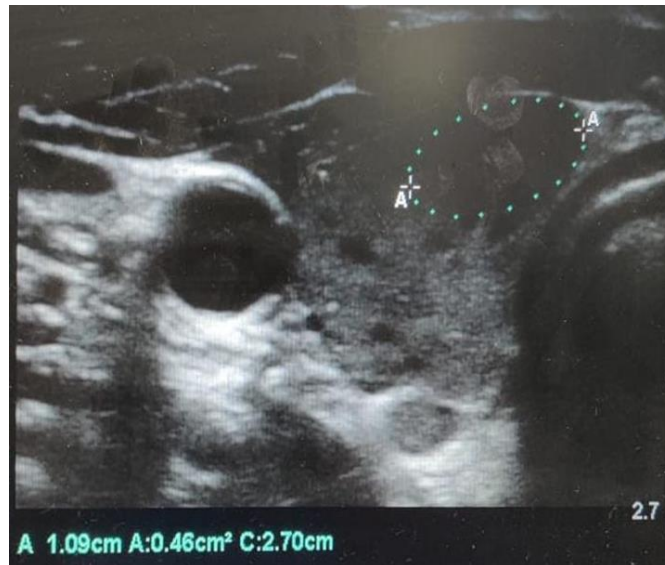

Fig. 3. Ultrasound of neck of right thyroid lobe showing 2.7x 1.09 cm hypoechoic lesion

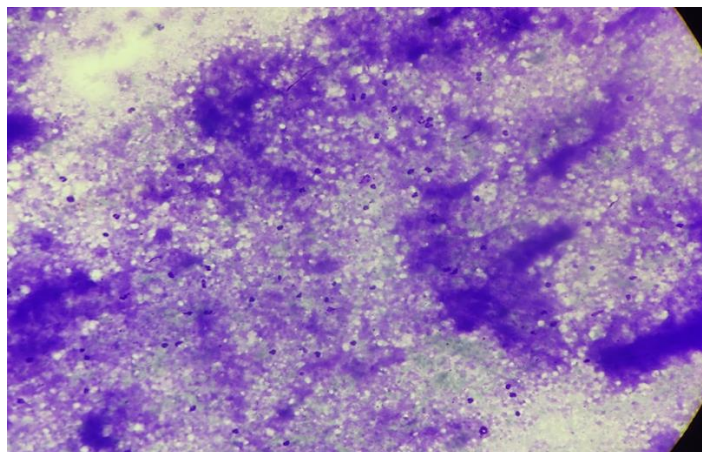


Fig. 4. Acid fast stain of thyroid FNAC aspirate(40x)

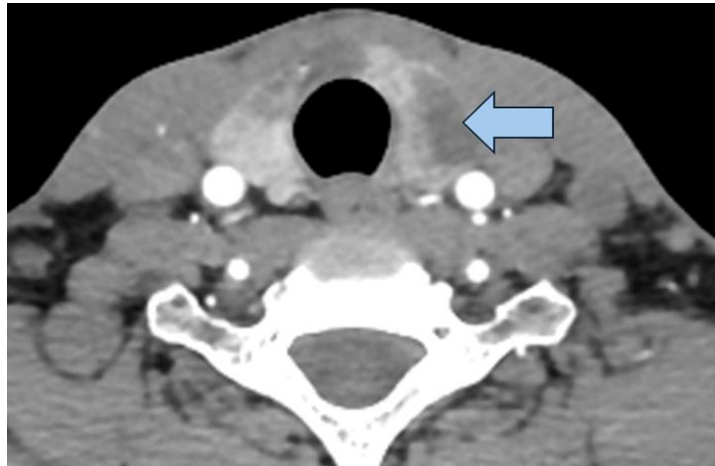

Fig. 5. CECT neck showing low density non enhancing ill-defined lobulated focal lesions involving both lobes of thyroid gland including isthmus

On thyroid function testing, the patient had TSH - 98.7 mIU/L, fT3 - 2.5 pg/mL, fT4 - 0.7 ng/dL, anti-TPO - 0.88 IU/mL. Ultrasonography (Fig. 3) of the neck showed multiple variable-sized hypoechoic lesions of the thyroid gland with lymph nodes, with the largest lymph node in the posterior triangle measuring 2.5 x 1 cm. FNAC of lymph nodes suggested positive for AFB STAIN. However, FNAC (Fig. 4) of the thyroid gland nodule was not suggestive of malignancy or tuberculosis. Due to the hypothyroid status, the patient was treated with thyroid replacement therapy. Considering the history of abdominal Koch's and active TB lymphadenitis with prolonged weight loss, lymphocytic predominance, borderline ADA in pericardial fluid, anti-tubercular drugs with steroids were started. CECT neck (Fig. 5) showed a low-density non-enhancing ill-defined lobulated focal lesion involving both lobes of the thyroid gland including the isthmus, with associated low-density possible necrotic multiple lymph nodes in the cervical region. TB-PCR of the FNAC aspirate was positive. The patient was discharged after removal of the pericardial catheter on thyroid hormone replacement and antitubercular treatment. On follow-up after 6 months, repeat echocardiography was normal, and the patient had no fresh complaints. The final diagnosis was kept as pericardial effusion secondary to hypothyroidism and tuberculosis (cervical + pericardial) with disseminated tuberculosis (cervical lymph nodes + thyroid).

3. DISCUSSION

Extrapulmonary tuberculosis is seen in 21.5% of cases, with very few reported cases of thyroid

tuberculosis even in TB-endemic countries [3]. The thyroid gland is considered immune to tuberculosis infection due to its rich vascular supply, lymphatics, iodine content, and thyroid capsule [4,5]. In our case, a 22-year-old male presented with cardiac tamponade, who was evaluated and found to be secondary to hypothyroidism and likely tuberculosis.

Further evaluation revealed cervical lymphadenopathy and nodular thyroid, confirmed to be tuberculosis of cervical lymph nodes and the thyroid gland through fine needle aspiration cytology (FNAC). Tubercular polymerase chain reaction (TB-PCR) of the FNAC aspirate played a crucial role in diagnosing the patient, as acid-fast staining was negative. Acid-fast stains have a high false negative rate in thyroid tuberculosis patients [6]. According to a study by Barnes et al., thyroid tuberculosis can be primary or secondary to dissemination from cervical lymph nodes or lungs [7]. Thyroid tuberculosis can manifest as various presentations including cystic lesions, acute abscesses, or solid nodules [8]. The frequency of primary thyroid tuberculosis ranges from 0.1-0.4% [9]. Patients with thyroid tuberculosis often have a euthyroid status but may occasionally develop hypothyroidism [10]. Many cases go undiagnosed due to being asymptomatic or presenting with non-specific complaints such as fever, malaise, fatigue, with preserved thyroid function in most cases [11]. A CT scan of the thyroid can be mistaken for thyroid gland malignancy [12].

The diagnosis of thyroid tuberculosis was made via ultrasound guided FNAC, avoiding the need for surgical intervention, and FNAC extracts

provided diagnostic clues. According to a study by Thirunavukkarasu et al., patients were treated with anti-tubercular drugs and thyroid hormone replacement for six months, [13] with significant improvement observed during follow-up, as was seen in our case.

4. CONCLUSION

Thyroid tuberculosis, though rare, can present with serious complications such as cardiac tamponade secondary to hypothyroidism. Diagnostic challenges arise due to the limitations of acid-fast staining in thyroid tuberculosis cases. Fine needle aspiration cytology (FNAC) with tubercular polymerase chain reaction (TB-PCR) proves to be a valuable tool for accurate diagnosis, enabling prompt initiation of appropriate treatment with anti-tubercular drugs and thyroid hormone replacement. Awareness of atypical presentations and judicious use of diagnostic modalities like ultrasound-guided FNAC are essential to avoid unnecessary surgical interventions. With proper management, patients with thyroid tuberculosis can achieve significant clinical improvement and outcomes. Early recognition and targeted therapy are crucial in optimizing patient care and outcomes in such uncommon yet clinically impactful cases.

CONSENT

As per international standards or university standards, patient(s) written consent has been collected and preserved by the author(s).

ETHICAL APPROVAL

It is not applicable.

ACKNOWLEDGEMENT

We would like to thank our medicine consultant Dr Akanksha Singh for guiding us and our pathology department for providing us slides.

COMPETING INTERESTS

Authors have declared that no competing interests exist.

REFERENCES

1. Emorinken A, Ugheoke AJ, Agbadaola OR, Dic-Ijiewere MO, Atiri A, Olugbemide O, Eifediyi RA. Prevalence and clinical

profile of tuberculosis patients in a rural teaching hospital in South-South Nigeria: A ten-year retrospective study. *Int J Trop Dis Health*. 2023; 44(8):33-42.

DOI:10.9734/ijtdh/2023/v44i81425

2. Luiz HV, Pereira BD, Silva TN, Veloza A, Matos C, Manita I, Cordeiro MC, Raimundo L, Portugal J. Thyroid tuberculosis with abnormal thyroid function-case report and review of the literature. *Endocrine Practice*. 2013, Mar 1;19(2):44-9.
3. European Centre for Disease Prevention and Control, WHO Regional Office for Europe. Tuberculosis surveillance and monitoring in Europe 2022 – 2020 data. Copenhagen: WHO Regional Office for Europe and Stockholm: European Centre for Disease Prevention and Control; 2022. Licence: CC BY 3.0 IGO.
4. Kataria SP, Tanwar P, Singh S, Kumar S. Primary tuberculosis of the thyroid gland: A case report. *Asian Pac J Trop Biomed*. 2012;2(10):839-840.
5. Pandit AA, Joshi AS, Ogale SB, Sheode JH. Tuberculosis of thyroid gland. *Indian J Tub*. 1997;44:205-207.
6. Ortiz-Flores A, Gioia F, Montanez-Fernandez L et al. Incidental finding of a primary thyroid tuberculosis. *Oxf Med Case Reports*. 2017;2017(6):omx022.
7. Barnes P, Weatherstone R. Tuberculosis of the thyroid: Two case reports. *Br J Dis Chest*. 1979;73(2):187-191.
8. Majid U, Islam N. Thyroid tuberculosis: A case series and a review of the literature. *J Thyroid Res*. 2011;2011: 359864.
9. Rankin FW, Graham AS. Tuberculosis of the thyroid gland. *Ann Surg*. 1932; 96(4):625-648.
10. Chaudhary A, Nayak B, Guleria S, Arora R, Gupta R, Sharma MC. Tuberculosis of the thyroid presenting as multinodular goiter with hypothyroidism: a rare presentation. *Indian J Pathol Microbiol*. 2010;53(3):579-581.
11. Modayil PC, Leslie A, Jacob A. Tuberculous infection of thyroid gland: A case report. *Med Case Reports*. 2009; 2009:416231.
12. Kang BC, Lee SW, Shim SS, Choi HY, Baek SY, Cheon YJ. US and CT

- findings of tuberculosis of the thyroid: three case reports. Clin Imaging. 2000;24(5):283-286.
13. Thirunavukkarasu S, et al. Tuberculous infection of the thyroid gland. Int Surg J. 2018, Jul;5(7):2679-2681.

© Copyright (2024): Author(s). The licensee is the journal publisher. This is an Open Access article distributed under the terms of the Creative Commons Attribution License (<http://creativecommons.org/licenses/by/4.0>), which permits unrestricted use, distribution, and reproduction in any medium, provided the original work is properly cited.

Peer-review history:

The peer review history for this paper can be accessed here:

<https://www.sdiarticle5.com/review-history/117633>