



# **Evaluation of Adhesions Underneath Laparoscopic Sterilization Scar in Patients Undergoing Abdominal Surgery**

**Ravi Singh Dogra<sup>1</sup>, Sanjeev Kumar<sup>2</sup>, Som Raj Mahajan<sup>2</sup>, Rajesh Chaudhary<sup>2\*</sup>,  
Poonam Dogra<sup>3</sup> and Vikrant Dharwal<sup>4</sup>**

<sup>1</sup>Department of Surgery, Civil Hospital Ghumarwin, HP, India.

<sup>2</sup>Department of Surgery, Dr. R.P. Govt. Medical College Kangra, Tanda, HP, India.

<sup>3</sup>Department of Anesthesia, Dr. R.P. Govt. Medical College Kangra, Tanda, HP, India.

<sup>4</sup>Department of Surgery, Zonal Hospital Mandi, HP, India.

## **Authors' contributions**

*This work was carried out in collaboration among all authors. Author RSD contributed substantially to the conception, design, acquisition of data, analysis and interpretation of data, drafting the article, critical revision of the article and final approval of the version to be published. Author RC contributed substantially to the conception and design, critical revision of the article and final approval of the version to be published. Authors SK, SRM, PD and VD contributed substantially to the conception and design, acquisition of data, critical revision of the article and final approval of the version to be published. All authors read and approved the final manuscript.*

## **Article Information**

DOI: 10.9734/JAMMR/2020/v32i630429

### Editor(s):

(1) Dr. Sevgul Donmez, Mugla Sitki Kocman University, Turkey.

### Reviewers:

(1) Marcel Cerqueira Cesar Machado, University of São Paulo, Brazil.

(2) Tariq Namad, USA.

(3) Deepak Verma, Dr. S. N. Medical College, India.

Complete Peer review History: <http://www.sdiarticle4.com/review-history/56680>

**Original Research Article**

**Received 22 February 2020**

**Accepted 29 April 2020**

**Published 05 May 2020**

## **ABSTRACT**

**Introduction:** The minimally invasive approach has become the method of choice for treating most benign abdominal diseases that require surgery. However, it is obvious that laparoscopic procedures are not risk free. The aim of this study was to evaluate the prevalence of intra abdominal adhesions underneath umbilical scar following laparoscopic sterilization, in patients who are undergoing abdominal surgeries.

**Materials and Methods:** The present study was a hospital based prospective observational study conducted in the Department of Surgery, Dr Rajendra Prasad Government Medical College (Dr.

\*Corresponding author: E-mail: [topgun.chaudhary@gmail.com](mailto:topgun.chaudhary@gmail.com);

RPGMC), Kangra at Tanda (HP). The study group consisted of patients admitted to department of surgery during a period of one year and who fulfilled inclusion criteria. During intraoperative period, they were examined for presence or absence of adhesions at the site of previous laparoscopic sterilization scar at Periumbilical area.

**Results:** Total of 60 patients were taken in this study. Two out of 60 (3.3%) patients had adhesions underneath previous Laparoscopic Sterilization scar around umbilicus and adhesive structure was omentum in both cases.

**Conclusion:** Adhesion formation is expected in any abdominal surgery whether open or laparoscopic surgery. In our study only 3.3% of patients had adhesions underneath previous laparoscopic sterilization scar in periumbilical region. Therefore umbilical port can be considered for re-entry of index port in next laparoscopic surgery, in patients with history of laparoscopic surgery through umbilical region.

*Keywords: Abdominal surgery; laparoscopic sterilization; portsite adhesions; umbilical scar.*

## 1. INTRODUCTION

In modern surgical practice laparoscopy is widely used for both diagnostic and therapeutic purposes. The minimally invasive approach has become the method of choice for treating most benign abdominal diseases that require surgery [1]. However, it is obvious that even laparoscopic procedures are not totally risk free. Index port entry in laparoscopy is a blind procedure, and complications may occur while attempting access to the peritoneal cavity and peritoneal access is associated with injuries to the gastrointestinal tract and major blood vessels. At least 50% of these major complications occur prior to commencement of the intended surgery. This complication rate has remained the same during the past 25 years [2,3]. As advances in laparoscopic skills and instrumentation evolve, increasingly complex procedures are being performed laparoscopically, yet most complications are associated with primary access. Risk increases in cases with history of previous surgery. A multicentric study from Netherlands reported a 0.1% complication rates in gynecologists who only used closed technique by either Veress needle or direct port entry. While in another group of gynecologists who used closed as well as open technique reported overall complication rates of 0.12% in closed technique versus 1.38% in open technique [2]. Despite considerable advances in endoscopic techniques and instrumentation, inadvertent and potentially avoidable entry injuries continue to occur. The bowel injuries are more common as compared to vascular injuries. Approximately 30-50% bowel injuries and 13-50% vascular injuries go unnoticed at the time of surgery leading to an increase in mortality rate of about 2.5-5% [4]. There is little evidence in literature to support a low incidence of adhesions following

laparoscopic surgery rather than open laparotomy [5-9]. Brill et al. [10] concluded that midline laparotomy scars were significantly more prone to the development of adhesions as compared to Pfannenstiel incisions. In most cases, the umbilicus remains the primary site of entry for a variety of laparoscopic procedures and adhesions at umbilical/ paraumbilical area will affect the safe insertion of primary trocar at this region. Intraabdominal adhesions increase the risk of injury during Laparoscopy, because the normal anatomy in such cases may be distorted [4]. Furthermore, hospital admissions attributed to the adhesions following the laparoscopic surgery have been demonstrated to be comparable to that of open surgical procedures. Rate of adhesion formation after laparotomy has been well studied [10], but decrease or absence of the adhesions following laparoscopic procedures is under reported. We set out to evaluate adhesion formation at umbilical/paraumbilical region following laparoscopic sterilization. Our study is mainly targeting the rural female population, which constitutes the major part of Indian population and this targeted population mostly undergoes various laparoscopic procedures for different surgical and gynecological causes. This study evaluated the chances of adhesions in laparoscopic procedures and also the safety of re-entry through umbilical/paraumbilical area.

## 2. MATERIALS AND METHODS

The present study was a hospital based prospective observational study conducted in the Department of Surgery, Dr Rajendra Prasad Government Medical College (Dr. RPGMC), Kangra at Tanda. The study group consisted of patients admitted to department of surgery during

a period of one year who fulfilled inclusion criteria. During intraoperative period, they were examined for, presence or absence of adhesions at the site of previous laparoscopic sterilization scar (peri umbilical), the type of adhesions and adhesive structure. Grading of adhesions was done according to proposed grading system. The involved subjects gave informed consent and an ethical clearance was taken from the institutional ethical committee. All those patients who had undergone laparoscopic sterilization in the past and were admitted for abdominal surgery either through laparoscopic or open surgical approach, were included in the study. Patients with a history of laparotomy, radiation therapy, chemotherapy, Koch's abdomen, inflammatory bowel disease, intestinal obstruction in the past, significant hepatosplenomegaly, portal hypertension, gastro/pancreatic masses and previous history of laparoscopic abdominal surgery through the umbilical incision, were excluded.

### 2.1 Proposed Grading of Adhesions

- I. Omental adhesions.
- II. Bowel adhesions.
- III. Both

Grade I, II and III were further divided into a, b suffixes.

- a- Thin fibrous band.
- b- Thick Fibrous Band.

### 2.2 Statistical Analysis

Data were presented as frequency, percentage, mean, and standard deviation.

### 3. RESULTS

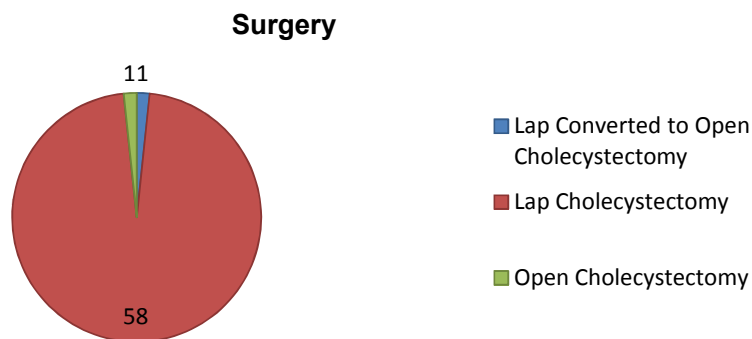
A total of 60 patients who had undergone laparoscopic sterilization in the past and were admitted for abdominal surgery either through laparoscopic or open surgical approach, were included in the study. The patient's age ranged from 29 years to 75 years with a mean age of 46.48 +/- 10.55 years. The patient's BMI ranged from 18 Kg/m<sup>2</sup> to 30 Kg/m<sup>2</sup> with a mean BMI of 22.61 +/- 2.77 Kg/m<sup>2</sup> (kilogram/square meter). Duration of surgery ranged from 45 min to 150 min with a mean duration of 71.95 +/- 23.23 min(minute) (Table 1).

**Table 1. Duration of surgery**

	Duration of surgery (minutes)
Minimum	45
Maximum	150
Mean	71.95
Standard Deviation	23.23

96.7% patients (n=58) underwent laparoscopic cholecystectomy and 1.7% patients (n=1) underwent open cholecystectomy and 1.7% patients (n=1), had laparoscopic cholecystectomy converted to open cholecystectomy (Fig. 1).

The previous lap sterilization Scar distance from umbilicus ranged from 1 cm to 4 cm with a mean distance of 2.12±0.46 cm and 76.7% scars (n=46) were clean while 23.3% scars (n=14) were wide. During present study, in 50% of the patients (n=30), access to abdomen was supraumbilical via Veress needle and Infraumbilical via Veress needle in 26.7% of the patients (n=16). In 21.7% of the patients (n=13), open technique was used through umbilical position (Table 2 & Fig. 2).



**Fig. 1. Pie-diagram showing types of surgery**

### Access to Abdomen

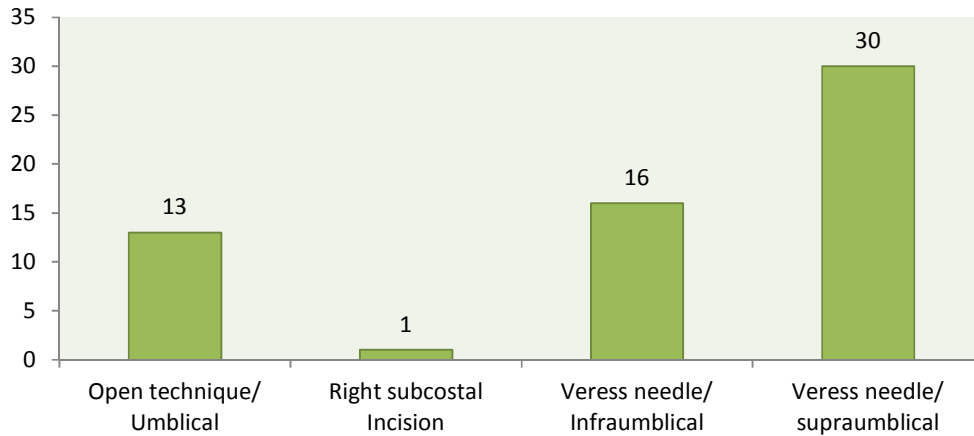


Fig. 2. Access to abdomen

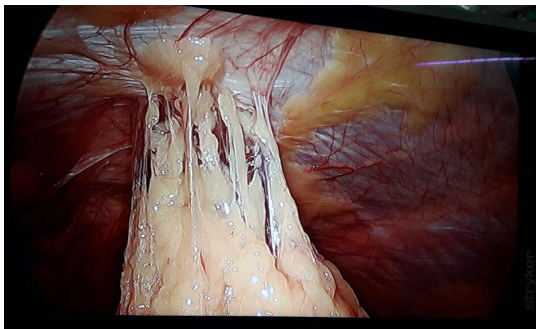


Fig. 3. Showing omental adhesions to the parietal wall

Table 2. Access to abdomen

	N	%
Open technique/Umbilical	13	21.7
Right subcostal Incision	1	1.7
Veress needle/Infraumbilical	16	26.7
Veress needle/supraumbilical	30	50.0

Umbilical adhesion was found in 3.3% (n=2) of the patients and Omentum was observed in 3.3% (n=2) as adhesive structure. Thick fibrous and thin fibrous adhesion was found in 1.7% patients each (Fig. 3). Apart from umbilical region adhesions at other sites were also noticed. Omental adhesions with gall bladder was present in 18.3% of the patients (n=11) and Omental adhesions with liver was observed in 1.7% patient (n=1). Postoperative complications were not observed in any of the patients. Duration of hospital stay was one day in 56.7% of the patients (n=34) and it was 2 days for 40% of the patients (n=24).

### 4. DISCUSSION

Any surgical disruption of the peritoneum leads to adhesion formation between bowel and the anterior abdominal wall. Even the smallest incisions, such as one made during laparoscopy, could result in significant adhesion formation and should alert the surgeon to take the necessary steps to avoid subsequent injury [5,6,7]. A primary port/Index port is the first entry site through which a laparoscope is introduced into peritoneal cavity. It is the most important and potentially dangerous first step in laparoscopic surgery. Injuries may occur due to advancing instruments toward the posterior abdominal wall and encountering anatomically normal but distended bowel or due to adhesions of viscera to the anterior abdominal wall. One of the studies, reviewing over 37000 gynaecological surgeries conducted in the USA, concluded that 37.9% bowel injuries occurred while inserting the index port trocar and 22% occurred while inserting the secondary trocar [4]. Laparoscopic procedures are the most favored surgical and gynecologic procedure performed now a day but despite advancements in instrumentation and techniques, inadvertent injury to the underlying viscera still occurs [1]. We observed that only 8% of the patients were elderly (>60 years). However, no general consensus has been reached in regards to the effect that age has on the formation of adhesions, however it is well agreed that there is a high incidence of adhesions at all ages. The Surgical and Clinical Adhesions Research (SCAR) trial examined the burden of adhesions following lower abdominal surgery and concluded that the risk of adhesion-

related readmission in the 5 years following surgery is higher in patients younger than 60 years age compared with those aged 60 years or older. Whereas the overall risk for these patients after surgical procedures was estimated to be approx. 5%, the risk was as high as 10% for women under the age of 60 years [11]. Our study demonstrates that the prevalence of umbilical adhesions following laparoscopy is higher than previously reported, umbilical adhesions were found in 3.3% patients and the adhesive structure was omentum in all cases. 20% patients had intraabdominal adhesions at sites other than umbilicus. Kaali & Barad [12] had evaluated 1133 women with prior abdominal surgery for the presence of adhesions and the rate of Intraumbilical adhesion was found to be 0.08%, whereas 25% patients had intra-abdominal adhesions at other sites. On the other hand, Audebert & Gomel [13] in a prospective study evaluated the presence of umbilical adhesions in patients with previous surgery and found that, 1.6% of patients with a prior laparoscopy had Intraumbilical adhesions. Sepilian et al. [14] in a retrospective review demonstrated high prevalence of Intraumbilical adhesions after previous laparoscopic surgery; they found that 32 of 152 (21.2%) patients with previous laparoscopy had umbilical adhesions. It is difficult to explain the reasons for higher incidence of Intraumbilical adhesion in our study. We believe this to be due to a small sample size and non standardization of the port entry and closure techniques. Another thing could be already existing pelvic inflammatory disease during the previous laparoscopic sterilization. Access into the peritoneal cavity is the most important step and challenge of laparoscopy, that is inserting surgical instruments through small incisions. As this access is blind procedure it is associated with injuries to the gastrointestinal tract and major blood vessels and at least 50% of these major complications occur prior to commencement of the intended surgery. This complication rate has remained same during past 25 years [2,9]. In our study access to abdomen was supraumbilical via Veress needle in 50% patients and Intraumbilical via Veress needle in 26.7% of the patients. In 21.7% of the patients, open technique was used through umbilical position. The three main complications during creation of pneumoperitoneum in minimal access surgery are bowel injuries, vascular injuries, and urological injuries. The rate of major complications in a study from Finland has been quoted to be 1.4/1000 procedures [15]. Further the rate of intestinal injuries was found to be

0.6%/1000 procedures. Urological injuries were 0.3/1000 procedures and vascular injuries were 0.1/1000. The minor vascular injuries are more common as compared to the major vascular injuries involving the aorta, inferior vena cava or iliac vessels. Urological injuries are more commonly seen after the gynaecological procedures [1,2]. In our study, the patient's Body Mass Index (BMI) ranged from 18 Kg/m<sup>2</sup> to 30 Kg/m<sup>2</sup> with a mean BMI of 22.61+/- 2.77 Kg/m<sup>2</sup>(kilogram/square meter). A study by Hurd et al. [16] found that the position of umbilicus in healthy females of reproductive age group was related to the BMI. The average caudal distance between umbilicus and the aortic bifurcation was found to be 0.4cm,2.4 cm and 2.9 cm in normal weight females having a BMI of <25kg/m<sup>2</sup>, overweight females with BMI between 25-30 kg/m<sup>2</sup> and in obese females with a BMI of > 30 kg/m<sup>2</sup> respectively. The surgical importance of this lies in the position of Veress needle to be maintained while attempting first entry into the abdominal cavity. In thin patients it should be about 45 degrees towards the pelvis. The position of Veress needle should be between 45-90 degrees in overweight and about 90 degrees in the fatty females [1]. In our study, none of the complications were observed, which suggest that entry technique and location doesn't make much difference in view of port insertion associated injuries. However as surgeons, we must be aware of possible complications encountered during index port insertion and an alternative entry point may be chosen in those cases where scars are present in periumbilical areas.

## 5. CONCLUSION

Adhesions formation are expected in any abdominal surgery whether open or laparoscopic surgery. In our study only 3.3% of patients had adhesions underneath laparoscopic sterilization scar in periumbilical region. Hence it can be concluded that for re-entry of index port, periumbilical region can be used in previously operated patients who have laparoscopic scar at umbilical region.

## 6. LIMITATIONS OF THE STUDY

Small sample size and, Patients with specific surgery (Lap Sterilization) were included.

## CONSENT AND ETHICAL APPROVAL

Written informed consent was obtained from each of the patients involved, after the clearance from the institutional ethics committee. A copy of

the written consent and certificate of approval by the institutional ethical committee is available for review by the Editor-in-Chief of this journal.

### COMPETING INTERESTS

Authors have declared that no competing interests exist.

### REFERENCES

1. Krishnakumar S, Tambe P. Entry complications in laparoscopic surgery. *J Gynaecol Endosc Surg.* 2009;1(1):4–11.
2. Jansen FW, Kolkman W, Bakkum EA, de Kroon CD, Trimbos-Kemper TC, Trimbos JB. Complications of laparoscopy: An inquiry about closed versus open-entry technique. *Am J Obstet Gynecol.* 2004; 190:634-8.
3. Varma R, Gupta JK. Laparoscopic entry techniques: Clinical guideline, national survey, and medico legal ramifications. *Surg Endosc.* 2008;22(12):2686–2697.
4. Chandler JG, Corson SL, Way LW. Three spectra of laparoscopic entry access injuries. *J Am Coll Surg.* 2001;192:478-91.
5. Filmar S, Gomel V, McComb PF. Operative laparoscopy versus open abdominal surgery: A comparative study on postoperative adhesion formation in the rat model. *Fertil Steril.* 1987;48:486–489.
6. Lundorff P. Treatment of ectopics and subsequent adhesion formation. *Prog Clin Biol Res.* 1993;381:139–147.
7. Bulletti C, Polli V, Negrini V, Giacomucci E, Flamigni C. Adhesion formation after laparoscopic myomectomy. *J Am Assoc Gynecol Laparosc.* 1996;3:533–536.
8. Levrant SG, Bieber EJ, Barnes RB. Anterior abdominal wall adhesions after laparotomy or laparoscopy. *J Am Assoc Gynecol Laparosc.* 1997;4:353–356.
9. Diamond MP, Daniell JF, Feste J, Surrey MW, McLaughlin DS, Friedman S, et al. Adhesion reformation and de novo adhesion formation after reproductive pelvic surgery. *Fertil Steril.* 1987;47:864-866.
10. Brill AI, Nezhat F, Nezhat CH, Nezhat C. The incidence of adhesions after prior laparotomy: A laparoscopic appraisal. *Obstet Gynecol.* 1995;85(2):269–272. DOI: 10.1016/0029-7844(94)00352-E
11. Parker MC, Wilson MS, Menzies D, et al. The SCAR-3 study: 5-year adhesion-related readmission risk following lower abdominal surgical procedures. *Colorectal Dis.* 2005;7(6):551–558. DOI: 10.1111/j.1463-1318.2005.00857.x
12. Kaali SG, Barad DH. Incidence of bowel injury due to dense adhesions at the sight of direct trocar insertion. *J Reprod Med.* 1992;37:617– 618.
13. Audebert AJ, Gomel V. Role of microlaparoscopy in the diagnosis of peritoneal and visceral adhesions and in the prevention of bowel injury associated with blind trocar insertion. *Fertil Steril.* 2000;73:631– 635.
14. Sepilian V, Ku L, Wong H, Liu CY, Phelps JY. Prevalence of infraumbilical adhesions in women with previous laparoscopy. *JLS.* 2007;11(1):41–4.
15. Harkki-Siren P, Sjöberg J, Kurki T. Major complications of laparoscopy: A follow-up Finnish study. *Obstet Gynecol.* 1999;94: 94-8.
16. Hurd WW, Bude RO, DeLancey JO, Pearl ML. The relationship of the umbilicus to the aortic bifurcation: Complications for laparoscopic technique. *Obstet Gynecol.* 1992;80:48-51.

© 2020 Dogra et al.; This is an Open Access article distributed under the terms of the Creative Commons Attribution License (<http://creativecommons.org/licenses/by/4.0>), which permits unrestricted use, distribution, and reproduction in any medium, provided the original work is properly cited.

*Peer-review history:*  
The peer review history for this paper can be accessed here:  
<http://www.sdiarticle4.com/review-history/56680>