

Short-Term Outcomes of Fibrin Glue Versus Absorbable Tackers for Mesh Fixation in Laparoscopic TAPP Inguinal Hernia Repair: A Randomised Clinical Trial

R MANISH¹, THARUN GANAPATHY CHITRAMBALAM², VIKRAM YOGISH³,
NIDHI GEORGE⁴, S GOWSICK⁵, AKHIL AVIRNENI⁶



ABSTRACT

Introduction: Hernia is defined as the protrusion of all or part of a viscus through the wall that contains it. Laparoscopic and tension-free open repairs are the two procedures that are being performed globally in inguinal hernia surgery.

Aim: To compare the benefits of fibrin glue versus absorbable tackers in laparoscopic Transabdominal Preperitoneal (TAPP) inguinal hernia repair and to appraise their outcomes.

Materials and Methods: A randomised clinical trial was conducted at a tertiary hospital of SRM Medical College Hospital and Research Centre, Chennai, Tamil Nadu, India for 18 months, from March 2021 to August 2022. Total of 54 patients who had laparoscopic TAPP hernia repairs were divided into two groups each with 27 participants, group A mesh fixed using fibrin glue and group B mesh fixed using absorbable tackers. All the patients were followed-up for atleast three months postsurgery. Operating time, postoperative pain and complications data were collected. The Chi-square and Unpaired t-test determined the statistical significance of the data.

Results: Total of 54 patients aged 18 to 60 years were included in the study with no significant differences (p -value=0.696). The same was true for gender (11 males and 43 females), with no significant differences (p -value=0.735) in group A and group B between male and female patients. In current study, there was a statistically significant difference in pain levels between groups after 24 hours, hours (group B: 5.33 ± 1.30 and group A: 6.56 ± 0.51) however, after 48 hours (group B: 4.07 ± 0.87 and group A: 4.63 ± 0.49) and 72 hours (group B: 2.74 ± 0.76 and group A: 2.63 ± 0.49), there was no significant difference in the severity of the pain between the groups. At one week follow-up the level of pain score was significantly different. There was also a significant difference in haematoma between groups (p -value=0.038). In addition, there was a significant difference in return to normal activities in one week (p -value=0.033), two weeks (p -value=0.022), and four weeks between groups (p -value=0.019).

Conclusion: The use of fibrin sealant for mesh fixation in TAPP surgery has superior short-term outcomes when compared to tackers in terms of postoperative pain, return to normal activities and reduced incidence of haematomas.

Keywords: Minimally invasive hernia surgery, Totally extra peritoneal repair, Transabdominal pre-peritoneal repair

INTRODUCTION

Hernia is an abnormal protrusion of a viscus through the wall of a cavity which normally contains it [1]. The most common kind of groin hernia is an inguinal hernia [2]. It happens when a defect in the lower abdominal wall allows abdominal tissue, such as omentum or an intestinal loop, to protrude through. An inguinal hernia that is uncomfortable or growing larger might be treated surgically. Surgery is the definitive management for inguinal hernias [3,4].

Laparoscopic and tension-free open repair procedures are two procedures that are being mastered globally in inguinal hernia surgery. Hernia surgery has progressed beyond a straight forward repair of the defect to reinforce the wall using prosthetics. The management of recurrence was challenging for surgeons since tissue healing was linked to a high recurrence rate. The development of tissue reinforcement mesh represented a revolution in hernia surgery [5,6]. The advantage of mesh repair over suture repair has been established by meta-analysis that compares the two types of repairs [7]. Several studies that showed significant recurrence rates for laparoscopic hernia surgery caused controversy at first [8,9]. But over the past ten years, laparoscopic surgery for hernia repair has improved outcomes by lowering chronic pain, recurrence rates, and allowing patients to resume regular activities faster [10].

Staples are considered the primary source of nerve damage in TAPP induce persistent pain. The fixation of the mesh over the muscle during the use of a spiral group B increases the risk of damage to the ilio-hypogastric nerve. These complications led surgeons to turn to alternative fixing techniques, including cyanoacrylate and human group A. Group A is a commercial tissue adhesive that contains thrombin and fibrinogen. The commercial product is a two-part system made from human plasma with more thrombin and fibrinogen [11,12]. The first component can find high fibrinogen concentrations, factor XIII, fibronectin, and other plasma proteins. Thrombin, calcium chloride, and an antifibrinolytic drug like aprotinin are all in the second component. It binds the mesh to the tissues by causing the activation of fibrinogen and thrombin by calcium chloride, creating and cross-linking fibrin, and developing polymerised fibrin chains, the final step of the coagulation cascade [13]. The fibrinogen component provides tensile strength, thrombin stimulates the growth of fibroblasts, and aprotinin, an antifibrinolytic drug, lengthens the lifespan of the sealant. Due to its haemostatic and adhesive qualities, group A has recently been used in numerous surgical procedures. Promising preliminary findings have demonstrated that the strength of group A-based mesh fixation is at least on par with that of staples. Even the integration of the mesh material was improved and accelerated by increased fibroblast activity [14].

There are relative risks and benefits to laparoscopic surgery for treating inguinal hernias, but not enough research has been done to determine which surgical repair method is superior [15]. There is still disagreement over the ideal approach for inguinal hernia surgery because the results of such studies are inconsistent and have a significant impact on clinical practice [16,17]. Therefore, the purpose of this study is to evaluate the advantages of fibrin glue versus absorbable tackers in laparoscopic inguinal hernia repair.

MATERIALS AND METHODS

This is a randomised clinical trial conducted at the Department of Surgery of a Tertiary Hospital of, SRM, Medical College Hospital and Research Centre, Chennai, Tamil Nadu, India for 18 months, from March 2021 to August 2022. This study was carried out after receiving Institutional Ethics Committee (IEC) approval (2429/IEC/2021).

In the current study, total 54 patients participated for the laparoscopic hernia repair after obtaining the informed consent. Cases were randomly assigned into two groups using simple randomisation method, each with 27 participants-

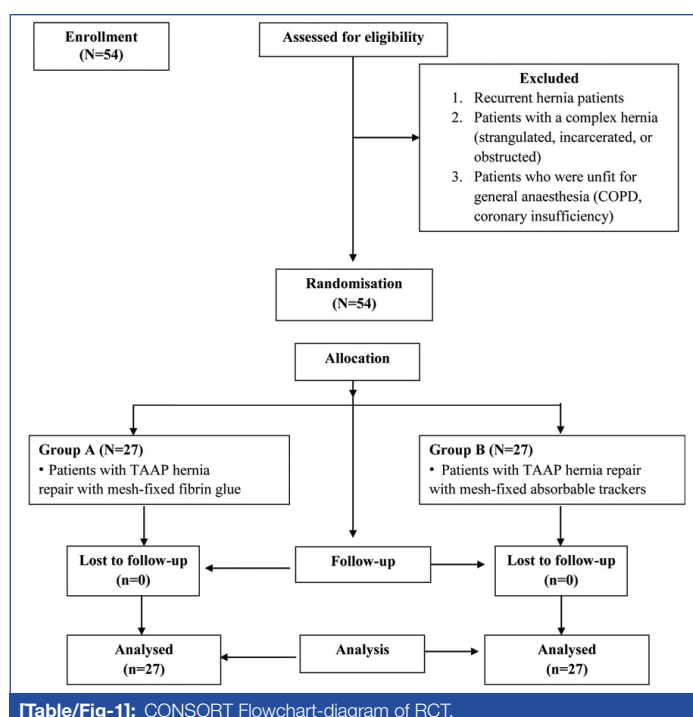
- Group-A included patients who had laparoscopic TAAP hernia repairs using mesh-fixed group A, and
- Group-B included patients who had laparoscopic TAAP hernia repairs using mesh-fixed absorbable group B.

Inclusion criteria: Every patient with a unilateral or bilateral inguinal hernia who was healthy enough for General Anaesthesia (GA) and aged 18 to 60 years were included in the study.

Exclusion criteria: Patients with recurrence, complicated hernias (strangulated, incarcerated, or obstructed) and who were unfit for GA [Chronic obstructive pulmonary disease (COPD), coronary insufficiency] were excluded from the study.

Procedure

Patients were evaluated using routine preoperative blood investigations, including complete blood count, coagulation profile, renal function tests, chest X-ray, urine routine, serology, and Electrocardiogram (ECG). Ultrasound (USG) abdomen was done for all patients to look for prostate size, and postvoidal residual urine. The preoperative evaluation also includes 2D echo and Pulmonary Function Tests (PFTs) in applicable patients. All patients were subjected to laparoscopic TAPP inguinal hernia repair with strict adherence to intraoperative surgical protocols and were operated by a single surgeon to reduce bias [Table/Fig-1].



[Table/Fig-1]: CONSORT Flowchart-diagram of RCT.

The following factors were taken into account following surgery to compare group A and absorbable group B for laparoscopic hernia repair:

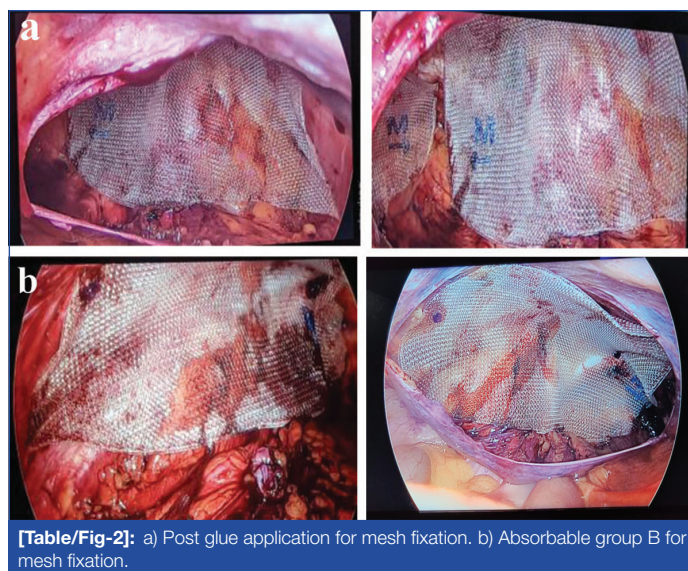
- Operating time;
- Postoperative pain were measured using a Numeric Rating Scale (NRS) based on a score of 0-10 for pain intensity, at 24 hours, 48 hours, 72 hours, one week, four weeks and three months following surgery [18];
- Clinical examination was used to evaluate seromas and haematomas;
- Getting back to normal activities, such as walking, climbing stairs, bathing, and other things.

STATISTICAL ANALYSIS

The statistical significance of the data was assessed using the Chi-square and Unpaired t-test. In addition, Statistical Package for Social Sciences (SPSS) software version 25.0 was used to analyse controlled data. Participants in the study were monitored for at least three months after the operation. A p-value<0.05 was considered to be significant.

RESULTS

In this study, fibrin glue and absorbable tackers were used in a similar number of patients across the different age groups, with no significant differences (p-value=0.696). In total, 9 patients with Diabetes Mellitus (DM), 3 patients with DM and Hypertension (HTN), and 6 patients with HTN were included in this study. The same was true for gender (11 males and 43 females), with no significant differences (p-value=0.735) in group A and group B between male and female patients. However, there were more patients who received fibrin glue and absorbable tackers on the right side (n=33) of the body than on the left side (n=21), but this difference was also not statistically significant (p-value=0.78) [Table/Fig-2].



[Table/Fig-2]: a) Post glue application for mesh fixation. b) Absorbable group B for mesh fixation.

The mean duration of surgery in group A was 71.00±3.18 minutes, while in the group B, it was 70.04±3.03 minutes. There was no significant difference in the duration of surgery between groups (p-value=0.125).

[Table/Fig-4] shows the mean and standard deviation of the pain scores at different time points after the surgery (24 hours, 48 hours, 72 hours, 1 week, 4 weeks and 3 months). The mean pain scores were higher at earlier time points after the surgery, and decreased over time. For patients who received fibrin glue, the mean pain scores were higher at 24 hours and 48 hours compared to the scores for patients who received absorbable tackers. At four weeks after the surgery, the mean pain score for both groups was zero, indicating that the patients in both groups had no pain at that time [Table/Fig-4].

Parameters	Group A	Group B	Total	p-value
Age (in years)				
<30	4	4	8	0.696
31-40	5	4	9	
41-50	10	7	17	
>51	8	12	20	
Gender				
Male	5	6	11	0.735
Female	22	21	43	
Co-morbidities				
DM	5	4	9	0.286
DM/HTN	0	3	3	
HTN	4	2	6	
Nil	18	18	36	
Side of Hernia repair				
Left	10	11	21	0.78
Right	17	16	33	

[Table/Fig-3]: Distribution of age, sex, co-morbidities, and side among the groups. Chi-square test; DM: Diabetes mellitus; HTN: Hypertension; A p-value<0.05 was considered to be significant

Pain	Group A (Mean±SD)	Group B (Mean±SD)	p-value
24 hours	6.56±0.51	5.33±1.30	<0.0001
48 hours	4.63±0.49	4.07±0.87	0.006
72 hours	2.63±0.49	2.74±0.76	0.008
1 week	1.52±0.51	2.22±0.70	<0.0001
4 week	0	0	0
3 month	0	0	0

[Table/Fig-4]: Comparison of postoperative pain among the group after different time intervals. Independent sample t-test; A p-value<0.05 was considered to be significant

In both the groups, seroma was in 1 (3.7%) patient each with no significant difference in between groups (p-value=1.000). Group A was free of haematoma (100%) and in group B, it was present in 4 patients (14.8%) with absence of haematoma in remaining 23 patients (85.2%). Two out of four patients with haematoma required aspiration with wide bore needle followed by compression dressing. Two patients were managed conservatively by serial USG monitoring [Table/Fig-5].

In group A, the return to normal activities in four weeks was present in 27 patients (100%) whereas, in group B, the return to normal activities in four weeks was in 22 patients (81.5%). There was a significant difference in return to normal activities in four weeks between groups (p-value=0.019) [Table/Fig-5].

Postoperative complications		Group A	Group B	p-value
Seroma	No	26 (96.3%)	26 (96.3%)	1.000
	Yes	1 (3.7%)	1 (3.7%)	
Haematoma	No	27 (100%)	23 (85.2%)	0.038
	Yes	0	4 (14.8%)	
Return to normal activities in 1 week	No	4 (14.8%)	11 (40.7%)	0.033
	Yes	23 (85.2%)	16 (59.3%)	
Return to normal activities in 2 weeks	No	1 (3.7%)	7 (25.9%)	0.022
	Yes	26 (96.3%)	20 (74.1%)	
Return to normal activities in 4 weeks	No	0	5 (18.5%)	0.019
	Yes	27 (100%)	22 (81.5%)	

[Table/Fig-5]: Comparison between groups for the postoperative complications and return to normal activities. Chi-square test; A p-value<0.05 was considered to be significant

DISCUSSION

This study compared the short-term outcomes of using fibrin glue versus absorbable tackers for mesh fixation in laparoscopic TAPP inguinal hernia repair. Pain in the group A was significantly more at 24 hours and 48 hours. However, the return to normal activities was better in the group A after four weeks. TAPP, or transabdominal preperitoneal, is a laparoscopic surgical technique used to repair inguinal hernias.

In present study, there were 5 male and 22 female participants in the group A procedure, and in the group B, there were 6 male and 21 female participants with the insignificant difference between the two groups (p-value=0.735). Andresen K et al., also reported a likely disassociation between the fixation method and gender distribution in 2017. Concerning co-morbidities, both the absence and presence of co-morbidities like DM, DM with HTN and HTN did not influence the type of treatment received [19]. Weltz AS et al., reported a similar but insignificant association with co-morbidities. They reported that the presence of DM and HTN among group A and group B patients was insignificant (p-value >0.05) [20]. Gender and co-morbidities, such as DM and HTN, did not significantly affect the choice of mesh fixation procedure.

The side of the inguinal hernia also did not influence the fixation method. The position of the hernia did not influence the mesh fixation method. The right side of the body had a greater involvement in the current study's group A (n=17) and group B (n=16) than the left side group A (n= 10) and group B (n=11), but this difference was also not statistically significant (p-value=0.78). This is also similar to the results of Hirsch H et al., [21]. They reported that the fixation type was also not influenced by whether the hernia was direct or indirect. Yet, they reported patients (14%) with both direct and indirect hernias [21]. Therefore, the type of hernia did not affect the type of mesh fixation.

The surgery duration for group A and group B did not differ. According to Karigoudar A et al., randomised prospective trial, using fibrin glue rather than prolene sutures for mesh fixation in Lichtenstein open inguinal hernia repair, reduced operating time, hospital stays and postoperative groin discomfort three months later [22]. However, in a study by Weltz AS et al., mesh fixation by fibrin glue took less time to operate than tackers that were not statistically significant [20].

The mean pain scores increased immediately following the procedure and then gradually decreased. Patients who received group A had mean pain scores that were higher at 24 and 48 hours. However, the pain scores in the group A were significantly lower than the group B at 72 hours and 1 week (p-value<0.001). Same was proven by Nizam S et al., in their randomised controlled single blinded study [23].

Barchi LC et al., reported the occurrence of seroma (4.7%) in hernia fixed with mesh on the 9th postoperative day [24]. No significant differences were found between the groups for secondary outcomes, except for a greater frequency of seroma development after glue fixation, according to Kaul A et al., [25]. Meta-analysis conducted by Shi Z et al., found that the use of the glue fixation arm in laparoscopic repairs was associated with an increased risk of seroma development [26]. The haematoma was also absent in those with fibrin glue, while four patients developed haematoma after fixation with tackers. The presence of haematoma varied among treatment groups with statistical significance.

The haematoma was also absent in those with group A, while four patients developed haematoma after fixation with group B. The presence of haematoma varied among treatment groups with statistical significance. According to a study conducted by Shi Z et al., there may be a small association between the use of hernia fixative mesh and group B and the development of seroma and haematoma. However, the association was considered to be insignificant [26]. A 27 and 22 patients belonging to treatment

groups fibrin glue and tackers returned to work in four weeks. Current work showed, in the group A, 27 people (100%) returned to their regular activities after four weeks. While in the group B, 22 (81.5%) people returned to their regular activities after four weeks. Return to regular activities in four weeks varied significantly between groups (p -value= 0.019). However, the recovery duration after two week within the groups was statistically insignificant. Andersen K et al., reported no variations in recovery time with the fixative treatment received [19].

Limitation(s)

The limitation of present study is that it was a single-centered study with shorter follow-up period. Further research with larger and more diverse samples, as well as longer follow-up periods, is needed to fully understand the effectiveness of the intervention.

CONCLUSION(S)

This study suggests that the use of fibrin glue for mesh fixation in TAAP may be a better option than tackers. Overall, the use of fibrin sealant for mesh fixation in TAPP surgery may offer several benefits compared to the use of tackers, including reduced postoperative pain, faster return to normal activities, and a lower incidence of complications such as haematomas. Further research is needed to confirm these findings and determine their clinical significance.

REFERENCES

- Malik A, Bell CM, Stukel TA, Urbach DR. Recurrence of inguinal hernias repaired in a large hernia surgical specialty hospital and general hospitals in Ontario, Canada. *Can J Surg*. 2016;59(1):19-25.
- Wani I. Double direct hernia, triple indirect hernia, double Pantaloon hernia (Jammu, Kashmir and Ladakh Hernia) with anomalous inferior epigastric artery: A case report. *Int J Surg Case Rep*. 2019;60:42-45.
- Srivastava V, Jha PK, Verma AK, Ansari MA. Triple inguinal hernia: rare clinical presentation. *BMJ Case Rep*. 2020;13(11):e238619.
- Bullen NL, Massey LH, Antoniou SA, Smart NJ, Fortelny RH. Open versus laparoscopic mesh repair of primary unilateral uncomplicated inguinal hernia: a systematic review with meta-analysis and trial sequential analysis. *Hernia*. 2019;23(3):461-72.
- Rea R, Falco P, Izzo D, Leongito M, Amato B. Laparoscopic ventral hernia repair with primary transperitoneal closure of the hernial defect. *BMC Surg*. 2012;12 (Suppl 1):S33.
- Attri MR, Bhardwaj R, Qadir Kar W, Ahmad Z, Singh B. Mesh fixation using fibrin glue sealant in laparoscopic inguinal hernia repair (TAPP and TEP): A prospective randomised study. *Jkscience.org*. 2018;20(3):136-40.
- Nguyen MT, Berger RL, Hicks SC, Davila JA, Li LT, Kao LS, et al. Comparison of outcomes of synthetic mesh vs suture repair of elective primary ventral herniorrhaphy: a systematic review and meta-analysis. *JAMA Surgery*. 2014;149(5):415-21.
- Liem MS, Van Duyn EB, van der Graaf Y, van Vroonhoven TJ, Coala Trial Group. Recurrences after conventional anterior and laparoscopic inguinal hernia repair: a randomised comparison. *Annals of Surgery*. 2003;237(1):136.
- Schjøth-Iversen L, Refsum A, Brudvik KW. Factors associated with hernia recurrence after laparoscopic total extraperitoneal repair for inguinal hernia: a 2-year prospective cohort study. *Hernia*. 2017;21(5):729-35.
- Karthikesalingam A, Markar SR, Holt PJ, Praseedom RK. Meta-analysis of randomised controlled trials comparing laparoscopic with open mesh repair of recurrent inguinal hernia. *Journal of British Surgery*. 2010;97(1):04-11.
- Odobasic A, Krdzalic G, Hodzic M, Hasukic S, Sehanovic A, Odobasic A. The role of fibrin glue polypropylene mesh fixation in open inguinal hernia repair. *Medical Archives*. 2014;68(2):90.
- Lovisetto F, Zonta S, Rota E, Mazzilli M, Bardone M, Bottero L, et al. Use of human fibrin glue (Tissucol) versus staples for mesh fixation in laparoscopic transabdominal preperitoneal hernioplasty: a prospective, randomised study. *Annals of Surgery*. 2007;245(2):222.
- Choi BJ, Jeong WJ, Lee SC. Fibrin glue versus staple mesh fixation in single-port laparoscopic totally extraperitoneal inguinal hernia repair: A propensity score-matched analysis. *International Journal of Surgery*. 2018;53:32-37.
- Ferrarese A, Marola S, Surace A, Borello A, Bindi M, Cumbo J, et al. Fibrin glue versus stapler fixation in laparoscopic transabdominal inguinal hernia repair: a single center 5-year experience and analysis of the results in the elderly. *International Journal of Surgery*. 2014;12 Suppl 2: S94-98.
- Filipi CJ, Gaston-Johansson F, McBride PJ, Murayama K, Gerhardt J, Cornet DA, et al. An assessment of pain and return to normal activity. Laparoscopic herniorrhaphy vs open tension-free Lichtenstein repair. *Surg Endosc*. 1996;10(10):983-86.
- Arregui ME, Navarrete J, Davis CJ, Castro D, Nagan RF. Laparoscopic inguinal herniorrhaphy: Techniques and controversies. *Surg Clin North Am*. 1993;73(3):513-27.
- Wellwood J, Sculpher MJ, Stoker D, Nicholls GJ, Geddes C, Whitehead A, et al. Randomised controlled trial of laparoscopic versus open mesh repair for inguinal hernia: Outcome and cost. *BMJ*. 1998;317(7151):103-10.
- Serlin RC, Mendoza TR, Nakamura Y, Edwards KR, Cleeland CS. When is cancer pain mild, moderate or severe? Grading pain severity by its interference with function. *Pain*. 1995;61(2):277-84.
- Andresen K, Fenger AQ, Burchard J, Pommergaard HC, Rosenberg J. Mesh fixation methods and chronic pain after transabdominal preperitoneal (TAPP) inguinal hernia surgery: a comparison between fibrin sealant and tacks. *Surg Endosc*. 2017;31(10):4077-84.
- Weltz AS, Sibia US, Zahir HR, Schoeneborn A, Park A, Belyansky I. Operative outcomes after open abdominal wall reconstruction with retromuscular mesh fixation using fibrin glue versus transfascial sutures. *Am Surg*. 2017;83(9):937-42.
- Hirsch H, Nagatomo K, Gefen J. Mesh fixation with fibrin sealant in totally extraperitoneal hernia repair. *J Laparoendosc Adv Surg Tech A*. 2017;27(3):259-63.
- Karigoudar A, Gupta AK, Mukharjee S, Gupta N, Durga CK. A prospective randomised study comparing fibrin glue versus Prolene suture for mesh fixation in Lichtenstein inguinal hernia repair. *Indian J Surg*. 2016;78(4):288-92.
- Nizam S, Saxena N, Yelamanchi R, Sana S, Kardam D. Mesh fixation with fibrin glue versus tackers in laparoscopic totally extraperitoneal inguinal hernia repair. *ANZ Journal of Surgery*. 2021;91(10):2086-90.
- Barchi LC, Franciss MY, Zilberstein B. Subcutaneous videosurgery for abdominal wall defects: A prospective observational study. *J Laparoendosc Adv Surg Tech A*. 2019;29(4):523-30.
- Kaul A, Hutfless S, Le H, Hamed SA, Tymitz K, Nguyen H, et al. Staple versus fibrin glue fixation in the laparoscopic total extraperitoneal repair of inguinal hernia: a systematic review and meta-analysis. *Surg Endosc*. 2012;26(5):1269-78.
- Shi Z, Fan X, Zhai S, Zhong X, Huang D. Fibrin glue versus staple for mesh fixation in the laparoscopic transabdominal preperitoneal repair of inguinal hernia: a meta-analysis and systematic review. *Surg Endosc*. 2017;31(2):527-37.

PARTICULARS OF CONTRIBUTORS:

- Junior Resident, Department of General Surgery, SRM Medical College Hospital and Research Centre, Chennai, Tamil Nadu, India.
- Professor, Department of General Surgery, SRM Medical College Hospital and Research Centre, Chennai, Tamil Nadu, India.
- Professor, Department of General Surgery, SRM Medical College Hospital and Research Centre, Chennai, Tamil Nadu, India.
- Junior Resident, Department of General Surgery, SRM Medical College Hospital and Research Centre, Chennai, Tamil Nadu, India.
- Junior Resident, Department of General Surgery, SRM Medical College Hospital and Research Centre, Chennai, Tamil Nadu, India.
- Junior Resident, Department of General Surgery, SRM Medical College Hospital and Research Centre, Chennai, Tamil Nadu, India.

NAME, ADDRESS, E-MAIL ID OF THE CORRESPONDING AUTHOR:

R Manish,
SRM Medical College Hospital and Research Centre,
Potheni, Kattan Kulathur, 603203, Chennai, Tamil Nadu, India.
E-mail: manishmarlecha97@gmail.com

AUTHOR DECLARATION:

- Financial or Other Competing Interests: None
- Was Ethics Committee Approval obtained for this study? Yes
- Was informed consent obtained from the subjects involved in the study? Yes
- For any images presented appropriate consent has been obtained from the subjects. NA

PLAGIARISM CHECKING METHODS: [Jan H et al.]

- Plagiarism X-checker: Oct 28, 2022
- Manual Googling: Jan 09, 2023
- iThenticate Software: Jan 27, 2023 (15%)

ETYMOLOGY: Author Origin

Date of Submission: Oct 26, 2022
Date of Peer Review: Nov 25, 2022
Date of Acceptance: Jan 28, 2023
Date of Publishing: Apr 01, 2023