



Primary Mucosal Melanoma of Upper Alveolar Ridge and Hard Palate – A Case Report

F. Massilamani¹, S. Kailasam¹, C. K. Vishnu Priya^{1*} and R. Poorani²

¹Department of Oral Medicine and Radiology, Ragas Dental College and Hospital, Uthandi, Chennai- 119, India.

²Department of Oral Pathology and Microbiology, Dr. Mohan's Diabetes Specialities Centre, Tambaram East, Chennai, India.

Authors' contributions

This work was carried out in collaboration between all authors. All authors read and approved the final manuscript.

Article Information

DOI: 10.9734/AORJ/2018/39053

Editor(s):

(1) Vaishali Kapoor, Department of Radiation Oncology, Washington University in St. Louis School of Medicine, St. Louis, USA.

Reviewers:

(1) Rajesh Balakrishnan, Christian Medical College, Tamil Nadu Dr. M.G.R. Medical University, India.

(2) Manas Bajpai, Nizam's Institute of Medical Sciences, NIMS Dental College, India.

(3) Deepak Pandiar, Institute of Medical Sciences, Banaras Hindu University, India.

(4) Ciro Dantas Soares, Piracicaba Dental School, State University of Campinas, Brazil.

(5) Sucheta Bansal, Himachal Pradesh University, India.

Complete Peer review History: <http://www.sciedomain.org/review-history/23117>

Case Study

Received 28th November 2017

Accepted 5th February 2018

Published 12th February 2018

ABSTRACT

Melanoma is a potentially aggressive malignant tumor that arises from melanocytes and is most commonly cutaneous in origin. Patients greater than 60 years of age have a higher incidence of malignant melanoma with a slight male predilection. Primary oral melanoma is an extremely rare malignant tumor. The predominant site of primary oral melanoma is the hard palate and maxillary alveolus. The asymptomatic early stage of the lesion makes the late diagnosis of the tumor. This article presents a rare case of malignant melanoma of maxilla with an asymptomatic palatal pigmentation.

Keywords: Oral melanoma; aggressive; melanocytes; hard palate.

1. INTRODUCTION

Mucosal malignant melanoma is an extremely rare malignancy and accounts for about 1.3% of all cancers [1]. Malignant melanoma has a higher prevalence in blacks, Japanese and Indians [1-5]. The incidence of primary oral malignant melanoma varies from 0.2% to 8% of all melanoma [1,3,5-9] and the common site of involvement is hard palate followed by maxillary gingiva [1,4,5]. Oral melanoma presents as pigmented macule or mass with a rapid growth rate [5,8]. The patients remain asymptomatic for a period of several months making the diagnosis difficult [5,10]. We report a case of asymptomatic primary malignant melanoma involving the upper alveolar ridge and hard palate.

2. CASE REPORT

A 71-year-old male patient reported to the Department of Oral Medicine and Radiology, Ragas Dental College and Hospital, Chennai with a complaint of missing teeth. The patient had no systemic illness and no history of adverse habits.

On clinical examination, diffuse hypo and hyperpigmented areas were evident in the hard palate. It was evident that during the prosthetic treatment, for the replacement of missing teeth there was a gradual progression of lesion in which the hyperpigmented areas were accompanied with a well-defined black coloured plaque within the duration of one month. The lesion was about 4x3 cm in size and present on the left side of the edentulous maxillary arch. It extends anteriorly from the alveolar ridge in relation to the clinically missing 22, 23, 24. Posteriorly 1cm short of the junction of the hard and soft palate, medially up to the midline and laterally till the edentulous alveolar ridge in relation to 26, 27(Fig. 1).

The surface over the lesion appeared rough and corrugated with ulceration over the centre of the lesion with an irregular border surrounded by whitish keratotic areas. The lesion was non-tender, non-scrapable with induration evident on palpation of the ulcerated area (Fig. 2). Entertain the notion of ABCDE criteria, after a complete clinical examination it is provisionally diagnosed as melanoma.

The clinical differential diagnosis taken into account are physiological pigmentation, melanotic nevi, melanotic macule, melanoplakia,

Addison's disease, peutz-jeughers, Kaposi's sarcoma. An incisional biopsy was done and the histopathological report revealed dysplastic surface epithelium. Atypical melanocytes are seen in the basal layer and invading the connective tissue stroma in forms of clusters and single cells. Atypical melanocytes exhibit features of nuclear pleomorphism and prominent nucleoli and the dense fibrous connective tissue shows a diffused chronic inflammatory cell infiltrate with moderate Vascularity which in favour of malignant melanoma histopathologically (Fig. 3). To confirm the diagnosis HMB 45 stain was done and shows positive (Fig. 4).

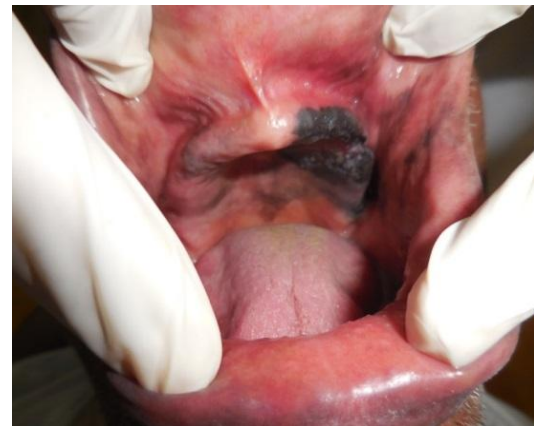

Fig. 1. Diffuse hypo and hyperpigmented areas of hard palate with amelanotic plaque

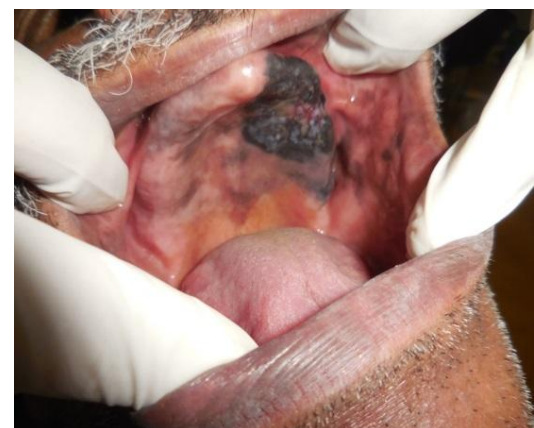

Fig. 2. Multiple asymmetric melanotic macules with an irregular border of the hard palate with an ulcerated melanotic plaque

The patient was advised for further investigation. The patient and her family were educated about the diagnosis, treatment options but the patient was not convinced for the treatment.

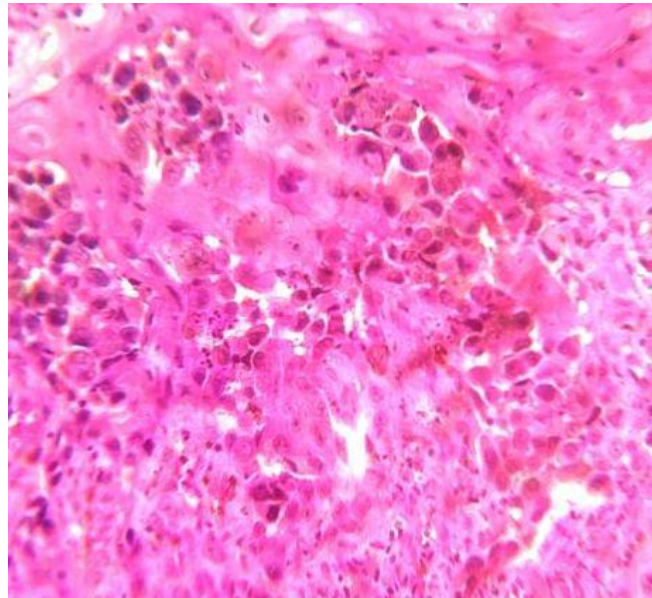


Fig. 3. Photomicrograph of hematoxylin and eosin stain section 40X showing dysplastic epithelium with atypical melanocytes invading the connective tissue

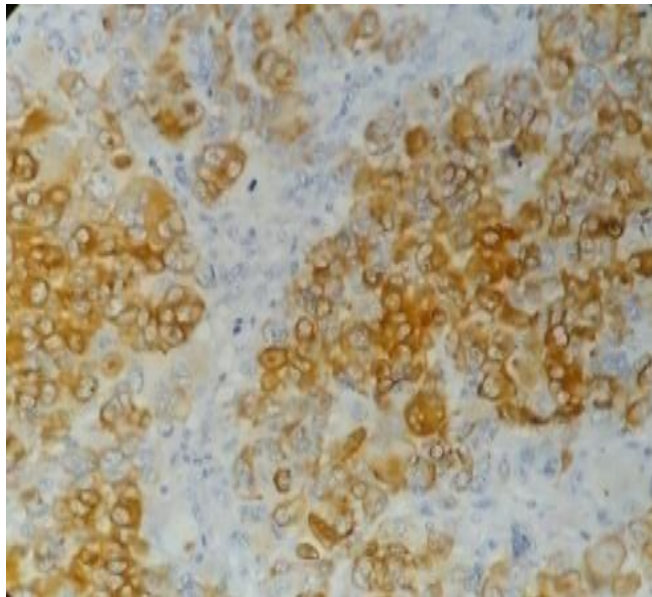


Fig. 4. IHC positive for HMB -45

3. DISCUSSION

Oral melanomas are malignant neoplasm of the melanocytes which is a neural crest cell derivative, present in the basal layer of the mucous membrane [4,10-12]. They may arise either from benign melanocytic lesion or from normal mucosa. The mucous membrane of nose, paranasal sinus, pharynx, and conjunctiva are also affected by melanoma [4]. The percentage of melanoma affecting the skin is 91.2%, eyes of about 5.2% and the mucosal surface is 1% in

which 55.4% of mucosal lesion affects the head and neck region [13].

The incidence of oral melanoma accounts for 0.2%-8% of all melanomas with 1.2% of new cases per 10 million per year [3,10,14]. Vanderwall et al. in his study reported 2.5% of all melanomas affects oral cavity whereas Robber son et al and Reddy et al estimated 0.4% to 1.3% of oral concurrence [3,13,14]. The prevalence of oral melanoma is greater for blacks, Japanese, Indians due to an increased

rate of melanin pigmentations in these races [1-4].

Oral melanoma is more prevalent among elderly male of age above 60 years. According to Rapini et al., more frequently affected age group for oral melanoma is between 41 to 60 years [9]. Incidence increases as age increases [15]. Oral melanoma is extremely rare in younger age group [9]. Hashenipour in his study found that male to female ratio is 2:1 with an age range of 56-77 years. Study of Barker et al., Hicks and Flaitz also agrees that melanoma has male predilection [3]. This is in accordance with our case where the patient was a 71-year-old male.

Oral melanoma has no specific etiology. In more than half of the oral melanoma patients, p53 gene alterations are noted with loss of expression of p16 which is a tumor suppressor gene [2,4,15,16]. loss of heterozygosity of 12p13 and p27kip1 is also noticed [2,4,16]. The possible etiological factors include mechanical trauma, ill-fitting denture, use of tobacco and formaldehyde exposure [1,2,4,5,8,12,15-18]. Inhalation and ingestion of environmental carcinogens at higher body temperature may also act as a triggering factor [4,15-17]. In our patient, the probable etiological factor may be mechanical trauma during the replacement of missing teeth since he is devoid of any adverse oral habits.

Oral melanoma may or may not follow the previous pigmentations [3,14,15,16,19]. Takagiet et al. showed 30-73% of melanoma is preceded by the pigmented lesion [5]. Umeda et al. reported that typical oral melanoma usually dispensed with three distinct components, central nodular component with brownish black pigmented plaque which is surrounded by a macule [4,15]. Tanka et al. found five types of clinical representation of oral melanoma namely pigmented nodular, non-pigmented nodular, pigmented macular, pigmented mixed, non-pigmented mixed tumor [2,3,4,14,16,17].

Oral melanoma most commonly involves hard palate (32%), maxillary gingiva (16%), followed by lower gingival mucosa (7%), buccal mucosa (7%), tongue (7%) and floor of the mouth [1,2]. In case of the secondary lesion, commonly involved sites are tongue followed by parotid and tonsils [2,14]. Oral melanoma in general usually starts as initial radial growth phase which is followed by sudden vertical growth phase which leads to invasion of the underlying tissues [15,19]. The

clinical presentation of oral melanoma varies from asymptomatic macule to a large exophytic growth with a wide colour variation. The lesion may later ulcerate, bleed and has rapid enlargement causing loosening of teeth [5,8,10,18]. Our patient had diffuse hyperpigmentations in the hard palate prior to the progression of the lesion. The lesion was an asymmetrical, irregular, blackish plaque with a diameter of more than 6mm accompanied with ulceration in the centre of the lesion that satisfies the ABCDE checklist of melanoma which is a commonly used tool for early detection of melanoma with acronym (Asymmetry, Border irregularity, Colour variegation, Diameter >6 mm and Evolution or history of change) [1,16,18].

Criteria for the diagnosis of primary oral melanoma was first proposed by Green et al in 1953 which includes, demonstration of clinical and microscopic tumor in the oral mucosa, junctional activity in the oral mucosa and inability to show any other primary site [4,8,12,13,15,16]. Our patient satisfies the above criteria since he was presented only with oral pigmentations. Union of international cancer control (UICC) distinguish malignant melanoma into three stages depending on their clinical and histologic findings as stage I-localized disease, stage II-regional lymph node metastasis, stage III-with distant metastasis [17].

Oral melanomas should be differentiated from other pigmented lesions occurring in the oral cavity such as physiological pigmentations, oral melanotic macule, smokers melanosis, melanotic nevi, amalgam tattoo, drug-induced pigmentations, melanoplakia, Addison's disease, peutz joghers syndrome, Kaposi's sarcoma [1,3,4,5,12,14,15,17,18]. According to the rule of thumb, a pigmented lesion with no changes lasting for more than five years are not considered as malignant melanoma and biopsy is not required [18]. The diagnosis is confirmed by histopathological examination using various markers specifically for melanoma.

The histological appearance of primary melanoma shows variations in nuclear size, shape and staining characteristics of melanocytes [2,5]. In case of amelanotic melanoma there will be scarce melanin or absence of melanin evident [3,13] and in these circumstances, immunohistochemistry should be mandatory. Western society of teachers of oral pathology (westop) workshop in the year 1995 held at Banff, Canada suggested that the oral

melanoma are recognizably different from nature of cutaneous melanoma and recommended to classify them into four histological patterns namely 1. In situ type which accounts for 15% of oral melanoma, 2. Invasive type amounts to 30%, 3. Combination type is a combination of invasive with in situ components which accounts for 55% of oral melanoma, 4. Atypical type [4,6,7,12,16,19].

Prasad et al. In 2004 proposed a classification which includes level 1-In situ mucosal melanoma without invasion, level 2-Invasion up to lamina propria, level 3- Deep invasion into bone, cartilage, skeletal muscle [6,10]. In our case, histopathology reveals the presence of atypical melanocytes on the basement membrane invading the connective tissue which falls under Westop type-II grading and level-II grading by Prasad et al.

The histologic feature of malignant melanoma has similar features of epithelial, mesenchymal, neural tumors [4,10,14]. Malignant melanoma has a histological differential diagnosis of malignant lymphoma and undifferentiated carcinoma [1,13], thus immunohistochemistry plays a vital role in differentiating melanoma from other malignancies. S-100 protein; melan-A (mart-1), HMB-45 (GP100) and tyrosinase can be very useful to distinguish primary oral melanoma from other malignancies. Ki-67 has been considered to be the most useful tool to estimate the variations in its biologic behavior and prognosis of melanoma. Ta90 immune complex (ta90ic), mia proteins are recently introduced markers for the assessment of the survival of the melanoma patients. Fatty acid synthase (FAS) is a useful marker to differentiate oral melanoma from melanocytic nevi. In case of amelanotic melanoma, the features usually mimic squamous cell carcinoma and in such circumstances, cytokeratin (CK) and leucocyte common antigen (LCA) is the useful markers to distinguish between them [13]. in recent days, fish (fluorescence in situ hybridization) is used to analyze the oral melanoma genetic markers [2]. Some authors suggested incisional biopsy or other invasive procedures may lead to the dissemination of tumor cells which may result in increased metastatic rate. According to Umeda et al., the five-year survival rate of patients with invasive procedures before definitive treatment is worst of about 25.9% and for patients with no such invasive procedures is 91.7%. Studies of Rampen et al. and Austin et al. also favors Umeda et al's result [2,16]. Batsakis's in his

study suggested that there is no evidence for metastatic dissemination following the preliminary incisional biopsy prior to the surgical resection [9]. It is known that dermoscopy has diagnostic accuracy in the pigmented skin lesions, where in case of mucosal melanoma it is not potentially used and it is not much awareness of dentist. Lin et al. study showed malignant pigmented lesion of the mucosa accounts 75% of multicomponent pattern and the homogeneous pattern is of 25% in the dermoscopy. In dermoscopy, the most common mucosal melanoma features in contrast to benign mucosal pigmented lesions were: asymmetry of structure, multiple colours, blue-white veil, irregular dots or globules, regression structure, blotches, irregular vessels and an irregular pigment network [20,21,22]. Excisional biopsy should carry out in case of the small lesion, and incisional biopsy for large lesion from the thickest and darkest area of the lesion [15].

Apart from histopathological examination, radiographic investigation of CT, MRI, positron-emission tomography may play a major role in the diagnosis of primary invasion and distant metastasis [13]. common site of metastasis are lungs, liver, brain, bones [4,5]. Our patient was not willing for treatment even after counseling since the presentation of the lesion was asymptomatic without obvious evolutionary changes.

No particular guidelines for treatment of oral melanoma exist till date. The management of oral melanoma is preferably surgery and it is more effective treatment modality. Surgery may get complicated by anatomic restraints of the lesion [7]. Electrodissection and cryosurgery may also be used in the treatment of melanoma in some cases [5]. Though melanoma is not classically radiosensitive, radiotherapy may be the choice of unresectable lesions [14]. Postoperative radiotherapy, adjuvant chemotherapy, immunotherapy has the influence in the survival rate of cutaneous melanomas but it has questionable benefit in the oral melanoma patients. The drug in use for melanoma treatment are dimethyl triazenoimidazole, carbonide, nimustine hydrochloride, vincristine and interleukin -2 as an immunotherapeutic agent. The recent treatment options include braf inhibition, systemic and intralesional administration of IL-2, imiquimod/toll-like like receptor activation, treatment with bacillus calmette-guerin, interferon therapy, oncolytic vaccines [13,23]. The efficacy of adjuvant

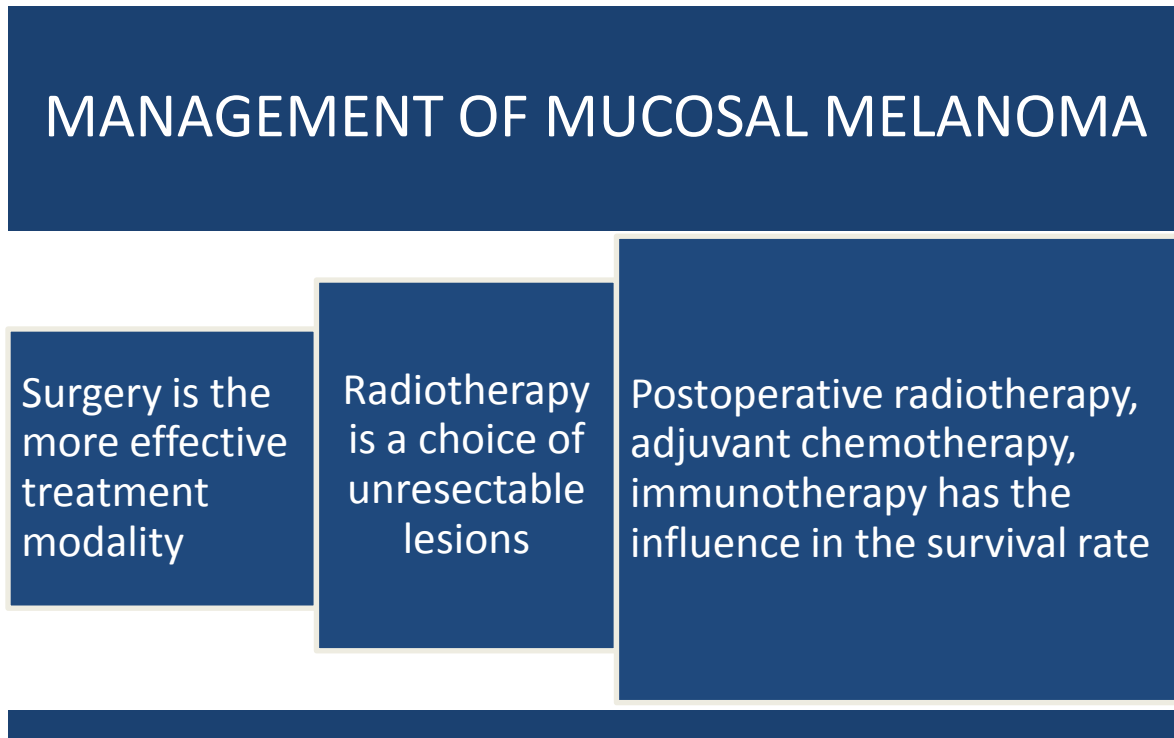


Fig. 5. Management of mucosal melanoma

treatment is monitored by tyrosinase mRNA amplification by reverse transcriptase polymerase chain reaction [2]. After the primary therapy, recurrence may occur even 10 to 15 years later [19]. During the follow up of postoperative cases, the presence of circulating melanoma cells are considered as the markers for the detection of high relapse risk and for shorter disease-free survival [2].

Prognosis of oral melanoma is extremely poor with 5 years survival rate of 5-20% due to its asymptomatic nature and late diagnosis [5,7]. Other factors which are contributing to the poor prognosis and survival rate of primary oral melanoma are tumor thickness of more than 5mm, morphology of tumor cells, anatomic restraints during surgery [3,15,19]. The survival rate of 5 years is comparatively better for gingival lesion than the palatal melanoma [16]. According to Vairaktaris et al., 5 year survival rate does not exceed 5-9% and Chaudhry et al. stated that the survival time after the point of diagnosis is 18 months [3,14].

4. CONCLUSION

Oral malignant melanoma is a highly aggressive and rare neoplasm with unclear etiopathogenesis and poor survival rate. The time of diagnosis is

directly related to the prognosis of the malignancy. But unfortunately, they are commonly diagnosed at their late stages because of its asymptomatic nature. Periodic evaluations of various pigmented lesions are mandatory with through clinical and histopathologic workup and wide knowledge about various treatment options.

CONSENT

We have obtained all appropriate patient consent form. In the form, the patient has given his consent for his images and other clinical information to be reported in the journal. The patients understand that his name and initials will not be published.

ETHICAL APPROVAL

It is not applicable.

COMPETING INTERESTS

Authors have declared that no competing interests exist.

REFERENCES

1. Jashandeep Kaur, Kunal Sood. Malignant melanoma of the oral cavity: A review.

- International Journal of Science and Research. 2015;4:664-6.
2. Nambiar, Vishwanath MN, Bhat S, Farzana f, Khwaja, Alrani d. Oral malignant melanoma: A brief review. *J Clin exp Pathol*. 2016;6.
 3. Ms Hashemi Pour. Malignant melanoma of the oral cavity: A review of literature. *Indian J Dentres*. 2008;19.
 4. Muralee Mohan, Vihang Y. Sukhadia, Deepak Pai, Smitha Bhat. Oral malignant melanoma: Systematic review of literature and report of two cases. *Oral surg oral med oral pathol oral Radiol*. 2013; 116:e247-e254.
 5. Aline Mie Uratani, Danyel Elias Da Cruz Perez, Pablo Agustin Vargas, Jacks Jorge, Marcio Ajudarte Lopes. Oral melanoma: review of the literature. *Braz J Oral Sci*. 2004;3:428-32.
 6. Hsieh Ricardo, Nico Marcello M, Claudia M. Camillo-coutinho, Fernandes Juliana, Clovis Antonio Lopes Pinto, Lourenco Silvia. Primary oral mucosal melanoma: A short review. *Journal of Pigmentary Disorders*. 2015;2.
 7. Kelly R. Magliocca, Matthew K. Rand, Lyndon D. Su, Joseph I. Helman. Melanoma-in-situ of the oral cavity. *Oral Oncology Extra*. 2006;42:46–8.
 8. Vijaykumar Biradar, Rahul Latturiya, Surekha Biradar. Late diagnosis of oral mucosal Melanoma: Case report. *Journal of Dental & Allied Sciences*. 2012;1(2):85-7.
 9. Ramlal Gantala, Uma M. Jangili, Tejaswi Katne, Srikanth G. Gotoor. Oral mucosal melanoma: A case report. *Journal of Indian Academy of Oral Medicine & Radiolog*. 2017;29(1).
 10. Juliana de Souza do Nascimento, Adalberto Mosqueda Taylor, Oslei Paes de Almeida, Bruno Augusto Benevenuto de Andrade. Primary oral melanoma: A case report with Immunohistochemical findings. *J Clin Exp Pathol*. 2014;4.
 11. Jae-young Kima, Hyunyoung Kima, Jung-Hwan Lima, Woong Nam. Treatment modality of malignant melanoma that metastasized to the mandible and multiple organs: a rare case report and the literature review. *Journal of Oral and Maxillofacial Surgery, Medicine, and Pathology*. 2015;27:398–401.
 12. Felice Femiano, Alessandro Lanza, Curzio Buonaiuto, Fernando Gombos, Federica di Spirito, Nicola Cirillo. Oral malignant melanoma: A review of the literature. *J oral Pathol Med*. 2008;37:383–88.
 13. Kai-yuan Hsiao, Chiang-shin Liu, Tung-yiu wong, Jehn-shyun Huang, ken- Chung chen, Tze- ta Huang. Oral mucosa malignant melanoma: Clinical features, Diagnosis, treatment, and a case report. *Journal of Dental Problems and Solutions* 2015;2:019-024.
 14. Elomrani F, Mouzount H, Ouziane I, Khmamouch R, Lkhoyali S, Boukir A, et al. Melanoma of the oral cavity: About two cases and review of literature. *International Journal of Clinical Medicine*. 2013;4:191-4.
 15. Olga Warszawik-hendzel, Monika Slowinska, Malgorzata Olszewska, lidia Rudnicka. Melanoma of the oral cavity: pathogenesis, dermoscopy, clinical features, staging and management. *J Dermatol Case Rep*. 2014;3:60-6.
 16. Marco Meleti, Rene Leemans C, Wolter J. Mooi, Paolo Vescovi, Isaac van der Waal. Oral Malignant melanoma: A review of the literature. *Oral oncology*. 2007;43:116–21.
 17. Hegde Vinuta, Naikmasur Venkatesh G, Burde Krishna N, Sirur Dharendra G, Hallikeri Kaveri. Oral malignant melanoma of the mandibular gingiva – a case report. *Int J Med Res Health Sci*. 2014;3:726-30.
 18. Ajit Auluck, Lewei Zhang, Rajeev Desai, Miriam P. Rosin. Primary malignant melanoma of Maxillary gingiva — a case report and review of the literature. *JCDA*. 2008;74:367-71.
 19. Neeraj Sharma. Primary oral malignant melanoma: Two case reports and review of Literature. Hindawi Publishing Corporation Case Reports in Dentistry; 2012.
 20. Malgorzata Olszewska, Agnieszka Banka, Renata Gorska, Olga Warszawik. Dermoscopy of pigmented oral lesions. *J Dermatol Case Rep*. 2008;3:43-48.
 21. Bajpai M, Pardhe N, Chandolia B. Malignant melanoma of oral cavity. *J Ayub Med Coll Abbottabad*. 2017;29(1):183.
 22. Bajpai M, Pardhe N. Dermoscopy and pigmented lesions of oral cavity. *Ankara Med J*. 2017;(3):189-91.
DOI: 10.17098/amj.339336

23. Emanuel Maverakis, Lynn A. Cornelius, melanoma – a review of current and future
Glen M. Bowen, Tiffany Phan, Falin B. treatment Options. Acta Derm Venereol.
Patel, Sarah Fitzmaurice, et al. Metastatic 2015;95:516–24.

© 2018 Massilamani et al.; This is an Open Access article distributed under the terms of the Creative Commons Attribution License (<http://creativecommons.org/licenses/by/4.0>), which permits unrestricted use, distribution, and reproduction in any medium, provided the original work is properly cited.

Peer-review history:

*The peer review history for this paper can be accessed here:
<http://www.sciencedomain.org/review-history/23117>*